

ABOUT SPECIFIC ENDONASAL EXTRACTION OF CYSTS OF THE MAXILLARY SINUS

**Karabaev Hurram
Esankulovich¹**

**Nasretidinova Maxzuna
Taxinovna²**

**Karabayeva Zilola
Khurramovna¹**

Xayitov Alisher Adxamovich²

EMAIL: luna1088@mail.ru

Received 20th April 2022,
Accepted 18th May 2022,
Online 22nd May 2022

ABSTRACT: Maxillary sinus cysts most often result from a blockage of the mucus-secreting gland and swelling of the mucous membrane. The method of choice in the treatment of patients with a cyst of the maxillary sinus remains surgical. In rhinology, sparing methods of surgical interventions are increasingly used, the atraumatic nature of which practically does not affect the further formation of the anatomical structures of the nose, paranasal sinuses and their physiological functions. We applied the technique of sparing endonasal removal of the cyst of the maxillary sinus through the lower nasal passage, with intact structures of the ostiomeatal complex, using a port guide. The gentle surgical intervention we have proposed is easier to tolerate than radical surgery on this sinus. Patients stayed in the hospital for 2 to 5 days.

KEYWORDS: Chronic sinusitis, maxillary sinus cysts, port guide.

¹Tashkent Pediatric Medical Institute,
Uzbekistan

²Samarkand State Medical Institute,
Republic of Uzbekistan, Samarkand

INTRODUCTION

Cysts of the maxillary sinus most often occur as a result of blockage of the outlet of the gland that secretes mucus, and swelling of the mucous membrane. At the same time, due to the accumulation of mucus, it increases in size, thins the bone wall of the maxillary sinus (more often the orbital one). A cyst can also form when the development of teeth is impaired. In such cases, a retention tooth is found in it. More often, cysts are located on the lower wall of the maxillary sinus. Clinically, it is manifested by persistent headache, a feeling of heaviness in the upper jaw, temple and forehead, pain in the teeth. The main method of diagnosis of this disease is multispiral computed tomography (MSCT) or radiography of the paranasal sinuses in two projections, which reveals a rounded, well-defined shadow, usually located on the lower wall of the sinus.

The method of choice in the treatment of patients with maxillary sinus cyst remains surgical. At the same time, it is known that children after the age of 7 years have a significant growth of the bones of the facial skeleton and surgical interventions on them during this period are undesirable. In addition, radical

surgery on the maxillary sinus leads to a violation of the physiological functions of the nose, vascularization and trophic mucosa. In connection with the above, in rhinology, sparing methods of surgical interventions are increasingly used, the atraumatic nature of which practically does not affect the further formation of the anatomical structures of the nose, paranasal sinuses and their physiological functions. These methods involve the preservation of organs and tissues in order to restore their functions. Among other things, endonasal opening of the maxillary sinus allows you to avoid complications.

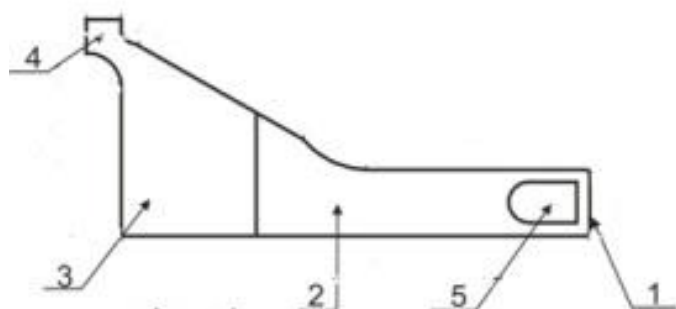
THE PURPOSE OF THE STUDY

Improvement of the surgical method of treatment of maxillary sinus cysts.

MATERIALS AND METHODS OF RESEARCH

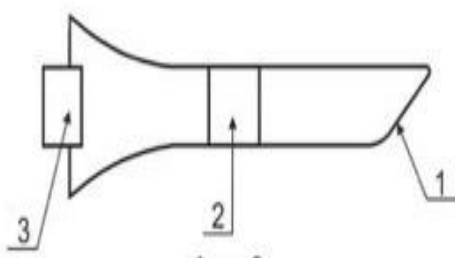
We observed 87 patients aged 18 to 45 years with a cyst of the maxillary sinus with a disease duration of 2 to 5 years. All patients underwent X-ray examination, computed tomography, which confirmed the presence of a cyst, before the operation they complained of headaches, difficulty in nasal breathing on the one hand, some had weakness, poor appetite, irritability.

We applied the technique of gentle endonasal removal of the maxillary sinus cyst through the lower nasal passage, with intact structures of the ostiomeatal complex, using a port guide.



Front view.

1-distal department, 2-the main part, 3-proximal part, 4-handle for the fixing, 5- hole inside the conductor



The view from the top.

1- distal department, 2- the main part, 3- proximal part.

Patients were operated in a sitting position under local anesthesia: lubrication of the nasal mucosa with epinephrine and the introduction of 2% novocaine solution in the anterior and middle parts of the lower nasal conch. in case of severe hypertrophy, its subluxation was performed.

After breaking and lifting the lower nasal conch, a _-shaped incision of 1.5x0.5 cm of soft tissues of the lateral wall of the lower nasal passage was made, retreating 1-1.5 cm from the crest of the lower nasal conch. The soft tissues were separated with a rasp, then an aperture of 0.5x1.0 cm was made with a boron or chisel. A port-conductor was inserted into the created hole, through which an endoscope with optics 00, 300 with a diameter of 2.7 mm was inserted to examine the sinus cavity and a shaver to remove the cyst. In a fistula formed after the operation has introduced a tampon with 5% liniment of syntomycin, the next day the tampon was removed and prior anemizatsii nasal mucosa with a 0.1% solution of adrenaline washed his bosom warm isotonic sodium chloride solution, furatsilina. If necessary, the washing was repeated.

Vasoconstrictor drops were instilled into the nose, general strengthening and immunocorrective therapy was prescribed. Endonasal removal of the maxillary sinus cyst on both sides lasts 15-20 minutes.

RESULTS OF THE STUDY

All the patients we operated on underwent the operation well, there were no complications in the postoperative period, they were discharged from the hospital on the 3rd-5th day, outpatient patients after 3-6 hours. Observations in the long-term period-1.3 and 6 months, 1 and 3 years after endonasal opening of the maxillary sinus, X-ray examination of pathological changes in the sinuses were not noted, they had no head pain, nasal breathing was free, there was no discharge in the nasal cavity.

CONCLUSIONS

The sparing surgical intervention proposed by us is more easily tolerated than radical surgery on this sinus. In the postoperative period, there is no swelling of the cheek and pain syndrome. Proposed port Explorer inkerala to simultaneously work with both hands, it is convenient to insert and withdraw the endoscope and shaver (or tongs) to remove the cyst from the sinus without injuring the mucous membrane of the lower nasal passage, which prevents the subsequent coarse of adhesions and reduces the operation time. The period of stay of patients in the hospital was from 2 to 5 days.

REFERENCES:

- [1]. I. S. Guryev, B. C. Piskunov Anatomical features of the middle nasal passage in patients with maxillary sinus cysts "Modern problems of audiology and rhinology". - Materials of scientific and practical conf. - Kursk, 2000. - p. 104-105.
- [2]. I. S. Guryev, F. N. Zavyalov, S. G. Elkovaidr Removal of cysts from the maxillary sinus under endoscopic control. Ros. rhinology-1998. No. 2. - p. 65.
- [3]. Kryukov A. I., Zarapkin G. Yu., Zayratyants O. V., Tovmasyan A. S., Arzamazov S. G., Gorovaya E. V., Fedotkina K. M. Anatomical and histological features of the state of the structures of the ostiomeatal complex in patients with cystic lesions of the maxillary sinus. Russian otorhinolaryngology. 2016;(2):60-65.
- [4]. Kryukov A. I., Scratchkin G. Yu., Tovmasyan A. S., Arzamazov S. G., Gorovaya E. V., Fedotkina K. M. Analysis of surgical approaches in the removal of maxillary sinus cysts. Russian rhinology. 2016;249(3):3-5.
- [5]. Nasretdinova M. T., Khayitov A. A., Salimova Sh. S. Improving the diagnosis of various forms of fungal rhinosinusitis //Bulletin of the doctor. - p. 27.
- [6]. Nasretdinova M. T., Kodirov O. N., Khushvakova N. J. Improvement of topical diagnostics and complex rehabilitation in children //Innovative technologies in children's medicine of the North Caucasus Federal District. – 2017. - pp. 219-223.
- [7]. Nasretdinova M. T., Khayitov A. A. Our tactics in the surgical treatment of cystic lesions of the maxillary sinuses.
- [8]. Shcheglov A. N., Kozlov B. C. NBI endoscopy in the diagnosis of diseases ENT organs// Russian Rhinology-2010. - No. 3. P. 52.

- [9]. Khayitov A. A. et al. Optimization of one-stage rehabilitation of the nasopharynx and tympanic cavity in recurrent exudative otitis media //Current scientific research in the modern world. - 2018. - no. 1-8. - pp. 81-84.
- [10]. Khayitov A. A., Khushvakova N. Zh., Nasretdinova M. T. Diagnostics of key cytokine parameters in patients with acute bacterial rhinosinusitis //Innovative technologies in children's medicine of the North Caucasus Federal District. – 2017. - pp. 93-95.
- [11]. Khayitov A. A., Nasretdinova M. T. Important aspects of etiopathogenesis, clinic, diagnosis and treatment of chronic cystic sinusitis / / Problems of Biology and Medicine-2020. No. 2(118) - pp. 213-216
- [12]. Khrustalev, E. V., T. Chantsev And Options of the pathological manifestations of cystic sinusitis on the basis of the review radiography and computed tomography data Materials of the XVIII Congress of otolaryngologists of Russia.-St. Petersburg, Russia.-2011.-P. 296-297.
- [13]. From S. N., Gusakova N. W., Hajitou A. A. Improvement of complex treatment of chronic hypertrophic rhinitis //Inter-medical. - 2014. - p. 46.
- [14]. Karabayev H.E. et all. Immunomodulatory therapy in the complex treatment of chronic cystic sinusitis//Central asian journal of medical and natural sciencesVolume: 01 Issue: 01 | March 2020
- [15]. Xayitov A.A. Immunological parameters in patients with chronic cystic sinusitis //Journal of critical reviews VOL 7, ISSUE 17, 2020