

EARLY DIAGNOSIS AND TREATMENT OF CHILDREN WITH HYPERTENSION-HYDROCEPHALUS SYNDROME ON THE BACKGROUND OF PROLONGED LABOR

Djurabekova Aziza Taxirovna¹

Muxammadiev Ravshan Tulkinovich²

Utaganova Guljaxon Xolmuminovna³

Turaev Azim⁴

Received 15th Aug 2021,

Accepted 26th Sep 2021,

Online 20th Oct 2021

ABSTRACT: According to the literature, all lesions of the perinatal period are conditionally divided into hypoxic-ischemic, arising from a lack of oxygen in the body, in particular the brain structure, traumatic and displaced genesis. As a result, the main syndrome of encephalopathy is hypertensive-hydrocephalic syndrome, which indicates an increase in the cerebrospinal fluid content and impairment of the cerebrospinal fluid pathways (3, 4).

Keywords: hypoxic-ischemic, traumatic and displaced genesis, hypertension-hydrocephalus syndrome, therapeutic approach.

¹Head of the Department of Neurology
Samarkand Medical Institute

²Master student of Neurology Department

³Candidate of Medical Science

Assistant at the Department of Neurology

⁴Clinical Resident of the Department
of Neurology Samarkand Medical Institute

Introduction

The manifestation of hypertension-hydrocephalic syndrome is a violation and swelling of the fontanel, in some cases, the divergence of the seams of the skull, the rigidity of the occipital muscles (1, 2, 3). In most cases, parents are worried about tremors (chin), poor sleep, without causal crying, regurgitation. At the same time, the child lags behind in psychomotor development (3, 4, 6). Moreover, all these listed clinical manifestations can make themselves felt only in the third or fourth month of life, which complicates the diagnosis, or rather its cause. Foreign authors, scientific publications, prefer to use the term "hydrocephalus", in which the ventricles are dilated, due to the discrepancy between the production and absorption of cerebrospinal fluid. The therapeutic approach to the problem remains open today, since it cannot reveal all the mechanisms of pathophysiology. Many literary sources describe complications in the long term, in the form of minimal cerebral dysfunction and more serious cortical changes (5). Accordingly, the development of diagnostic tactics in the early

stages and timely treatment of hypertensive-hydrocephalic syndrome is a priority, relevant, for assessing and preventing the progression of the disease.

Purpose of work. To compare clinical and diagnostic data in the early period of hypertensive-hydrocephalic syndrome in children, taking into account the proposed therapy.

Material and research methods. The examination included children with hypertensive-hydrocephalic syndrome (HHS) against the background of perinatal encephalopathy (post-hypoxic genesis and hypoxic-traumatic lesions), in the amount of 35 children, for the period 2020-2021, on the basis of the 1-Clinic of SamMI, the department of neonatology and child neurology; 20 children a group of healthy children control. The age of children is from birth (0) to 1 year. All children of group 1 at birth had a history of a burdened obstetric history (large fetus, functional narrow pelvis of the mother, weakness of labor, cord entanglement, breech presentation (in 2 cases, the transverse position of the fetus), etc. Traditionally, children were examined Neurosonography, in some cases, brain imaging (CT / MRI), was the main research method.

To assess the state of hemodynamics at the sub cranial and transcranial levels, we used duplex scanning of the great vessels of the head. Studied the patency of the vessels, anomaly (or rather, the presence of a special course of blood vessels), venous outflow. The data obtained were processed on an individual computer, the statistical criteria were used standard according to Student.

Research results. The examination of children began with the identification of structural features of the head and neck. Taking into account the norm, the size of the head volume by the year should not exceed 45-46 cm. Children in the main group differed in an increased rate of head growth compared to the norm, by 47% on average. In 4 children, a divergence of the sutures was noted, in 7 children, a pulsation of the fontanel was found. In 10 cases, an increase in the vascular pattern on the scalp was noted (sometimes not permanently), which confirmed venous dysfunction. Psychomotor development was assessed using the Shurba-Mastyukova scale. There was a delay in psychomotor development in the main group in 18 cases by 23 points, in the rest of the children, there were also significant changes in the motor-motor ratio, by 20-21 points, in comparison with the healthy group of children.

On radiographs in the children of the main group, a displacement of the cervical vertebrae was noted in 52%, in 12 children, compression was revealed in the lumbosacral region at the S1-S2 level, here, in 3 children, a displacement at the S2 level with respect to S3 was noted.

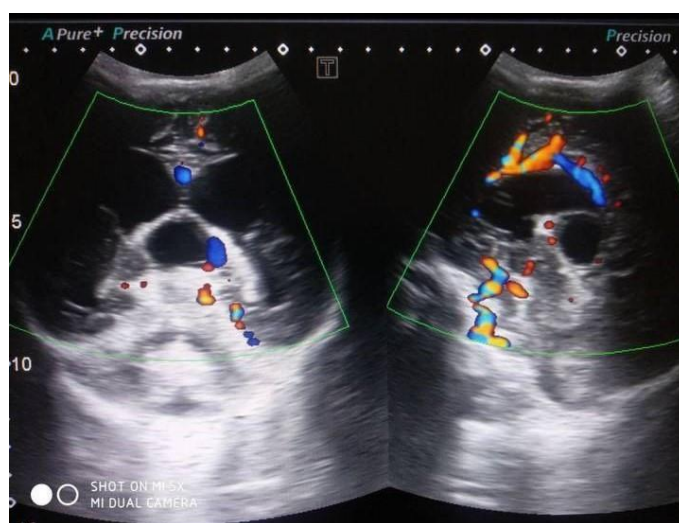


Figure. 1. Patient A., age 4 months.

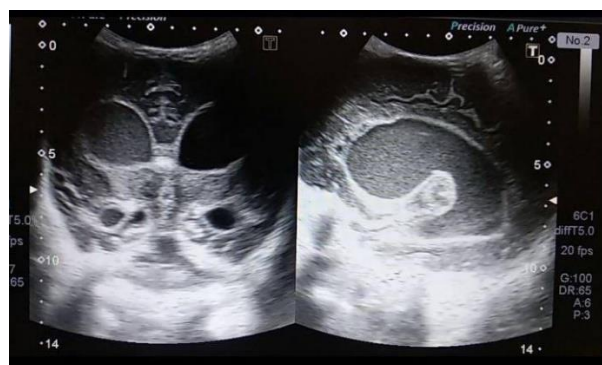

Figure. 2. Patient C., age 4.5 months.

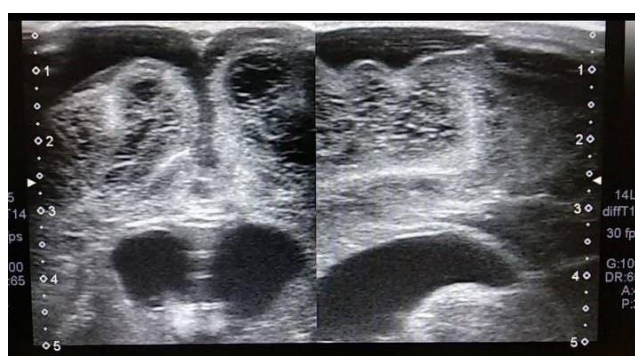


Figure. 3. Patient B., 6 months old .

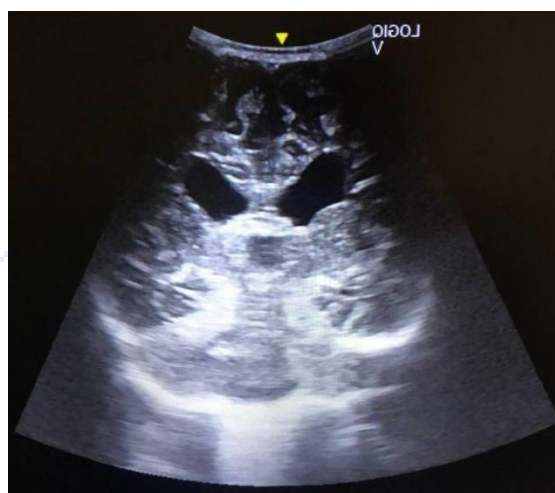

Figure. 4. Patient G., 6 months old .

The data of neurosonography turned out to be indicative (Fig. 1, 2, 3, 4). So, almost all children of the main group showed enlargement of the lateral ventricles and the body index of the lateral ventricle, respectively, was higher than normal, more than 25. In half of the cases, the expansion of the third ventricle by 2-3 mm was observed, 70% of the children of the main group showed an increase in the interhemispheric gap. Indicators of venous blood flow were no less important in this study. At the same time, the presence of venous dysgenia in the jugular vein was noted, quite pronounced, compared with the norm, in the overwhelming number of children of the main group (83%). In the vertebral veins, venous dysgenia, differing in level of degree, is noted in 33% of cases in the main group, of which only 5 cases are severely impaired. The study of arterial blood flow at the level of the vertebrobasilar basin revealed a slight asymmetry of the linear blood flow velocity in the vertebral arteries. All children of the second, healthy group did not find any pathological abnormalities, there were no complaints from their parents, the children corresponded to the age norm (Table 1).

Table 1: Hemodynamic parameters in children with hypertensive-hydrocephalic syndromes on the background of protracted labor

Indicators		Main group (n = 35)	Control group (n = 20)
ZMA	Vm	39.50	41.00
PA (V4)	Vm	28,00	35,00
	PI	0.66	0.64
PA (V2)	Vm	35.50	42,00
	RI	0.61	0.58

The next stage in the work was the provision of therapeutic assistance. In this regard, the children of the main group (35 children) were divided into two subgroups, 1 (18 children) underwent traditional therapy, with the inclusion of nootropics, dehydration, vitamin therapy, physiotherapy (the dose and selection of drugs were carried out on an individual basis). In subgroup 2 (17 children), L-lysine escinate was added to the treatment with nootropics (in particular cortexin) (on average, 1-year-old children 2 ml per 50 ml of saline solution intravenously up to 5 injections, once a day), and physiotherapy was replaced the correct laying of the head, a pillow under the head, the help of the Chance collar, and rigid swaddling, to strengthen the lumbosacral region. A repeated diagnostic examination was carried out a month later, according to the indicators of the primary observation. According to the parents, for the first week, the children reduced anxiety, causeless crying, especially in a horizontal position, stopped spitting up food after feeding, improved sleep and wakefulness. During a neurological examination. Children hold their head better (no rolling back was observed), the strength in the hands increased, children step on their feet (full foot). All these positive signs were observed in subgroup 2 of children in 100%, in 66% in 1 subgroup. According to neurosonography, the structure of liquor-containing systems normalized in 90% in subgroup 2 and only 31% in subgroup 1. No deterioration was observed in both subgroups, stabilization of the process was noted in 42% of cases of the main group. Duplex scanning in dynamics showed the normalization of the process of venous blood flow in the 2nd subgroup in most cases 81%, high rates of improvement were from the side of arterial blood flow. In subgroup 1, despite the positive clinical signs, venous hemodynamics was lower in terms of indicators, only in 33% it was changed in the positive direction. But hemodynamic deterioration was noted only in 2 children of the 1st subgroup. The growth rate of the head exceeded the norm, the divergence of the sutures did not decrease, which led to the obligatory further observation and treatment of the neurosurgical profile.

Thus, the results obtained allowed us to draw a certain conclusion, children with hypertensive-hydrocephalic syndrome against the background of perinatal lesions of the nervous system need a diagnostic examination, not only of a clinical and neurological nature, but also of neurophysiological (NSH) and neuroimaging (CT / MRI) at necessary and insufficiently informative ultrasound data, or tending to deteriorate the process. Duplex scanning of the hemodynamics of the great vessels should be studied in cases of overdiagnosis of hypertensive-hydrocephalic syndrome, or suspicion (exclusion) of vascular anomalies, the information content of the method is beyond doubt.

CONCLUSIONS

1. Liquorodynamic disturbances in children in the first months after birth are usually associated with difficult, protracted labor, with a displacement of the level of the cervical and sacral vertebrae (with improper head rotation during the period of labor). Such children need early diagnosis and identification of the causes of hypertensive-hydrocephalic syndrome

2. In accordance with the examination algorithm to standard methods (clinical and neurological examination), neurosonography, duplex scanning of the great vessels, radiography of the lumbosacral and cervical spine and, if necessary, neuroimaging of the head and neck are recommended.
3. To improve, first of all, venous dysfunction, to optimize therapeutic treatment, it is proposed to use the drug L-lysine escinate (in accordance with age), fixation of the neck with the Chance collar and complete rest in the lumbosacral region.
4. Control over the increase in head size, divergence of the cranial sutures, in the absence of stabilization of the process and progression of the hypertensive-hydrocephalic syndrome of observation in the neurosurgical profile

LITERATURE:

1. Igamova S.S., Djurabekova A.T., Shomurodova D.S., Niezov Sh.T. Fundamentals of the effectiveness of the health-improving methodology of children who have undergone perinatal lesions of the central nervous system // JOURNAL "Questions of Science and Education", 2019, p. 123-134
2. Clinical example No. 5. Diagnosis: Syringobulbia, syringomyelia of the cervical and thoracic spine, internal occlusive hydrocephalus, hydrocephalic-hypertensive syndrome, subcompensation // https://neuronsk.ru/for-doctor/clinical-examples/?ELEMENT_ID=1523
3. Ignatenkova T.V., Avdeeva T.G., Yudel'son Ya.B. Features of rehabilitation of children with perinatal lesions of the central nervous system with hypertensive-hydrocephalic syndrome // J. Polyclinic, No. 1 2006 (p. 44)
4. Egorova I.A. Hypertensive-hydrocephalic syndrome in children during the first three months of life (diagnosis and rehabilitation). // Dis ... candidate of medical sciences, St. Petersburg - 2003, 139 p.
5. Gromova L.L. Hypertensive-hydrocephalic syndrome and syndrome of benign intracranial hypertension in young children // Pediatric Bulletin of the Southern Urals, No. 2, 2013, p. 65-67
6. G.V. Klitochenko, N.V. Malyuzhinskaya Treatment of the consequences of perinatal damage to the central nervous system in children // Medicinal Bulletin No. 1 (73). 2019. Vol. 13, p. 42-46