

Article

# A Comparative Study to Evaluate The Effect of Metformin and Biosynthesised Zinc Oxide Nanoparticles on Liver Tissue and Some Enzymes In Alloxan-Induced Diabetic Rats

Yasameen Nihad Jasim<sup>1\*</sup>, Makarim Moustafa Kamal Asaad<sup>2</sup>, Liqaa Hussein AL-Samarrai<sup>3</sup>

<sup>123</sup> Departement of Biology, College of Education, University of Samarra, Iraq

\* Correspondence: [eduhm230172@gmail.com](mailto:eduhm230172@gmail.com)

**Abstract:** Diabetes is one of the well-known and chronic diseases caused by the lack of insulin production or its non-use by cells, and the most famous types of diabetes are type 1 and type 2 diabetes, and several treatments and programmes have been used to prevent it. In recent years, researchers have turned their thoughts to the field of nanotechnology and its use as an antidiabetic, so their concern was to find a safe, easy and inexpensive way to manufacture nanoparticles using plant extracts. The biosynthesis of nanoparticles using plant extracts was the best method, so The aim of the study was to compare the effect of metformin and biosynthesised zinc oxide nanoparticles on liver tissue and some enzymes in male alloxan-induced diabetic rats. Zinc oxide nanoparticles were made from *Eruca vesicaria* leaf extract and after observing the colour change, the nanoparticles were sent for confirmation and the required tests were performed including spectrophotometric (UV-Vis), X-ray fluorescence and transmission electron microscopy. The efficacy of zinc nanoparticles was studied and compared to metformin using 35 male albino rats that were induced to diabetes by alloxan and the rats were dosed for one month after which chemical tests of liver enzymes (Aspartate transaminase, Alanine transaminase) and histological sections of the liver were performed. The findings showed that *Eruca vesicaria* extract can be used to create ZnO nanoparticles. Results from a UV/Vis spectrophotometer indicated that it had an absorbance at 377 nm, X-ray diffraction spectroscopy (X-Ray) revealed eight absorption peaks and a crystalline size of 31.21 nm, and Transmission Electron Microscopy revealed that ZnO NPs were 54 nm in size and nearly spherical in shape. The results of measuring the liver enzymes aspartate transaminase (AST) and alanine transaminase (ALT) and comparing them between the treatments showed that there were significant differences between the treatments as it was found that alloxan treatment significantly increased the level of enzymes compared to the control. The results also showed that zinc nanoparticles reduced the level of liver enzymes after treatment with alloxan, which proves the effectiveness of zinc nanoparticles and metformin drug was also found to reduce the level of liver enzymes and the results of histological examinations showed. The results of our study found that plant extracts are effective in synthesising ZnO nanoparticles and that it is an easy, safe, environmentally friendly and inexpensive method. The study also found that biosynthesised ZnO nanoparticles can be used as an antidiabetic compared to metformin as ZnO nanoparticles showed protection of liver tissue and improvement in liver enzyme concentrations.

**Citation:** Jasim, Y, N. A Comparative Study to Evaluate The Effect of Metformin and Biosynthesised Zinc Oxide Nanoparticles on Liver Tissue and Some Enzymes In Alloxan-Induced Diabetic Rats. Central Asian Journal of Medical and Natural Science 2024, 6(1), 23-33.

Received: 10<sup>th</sup> Oct 2024  
Revised: 11<sup>th</sup> Nov 2024  
Accepted: 24<sup>th</sup> Dec 2024  
Published: 21<sup>th</sup> Jan 2025



**Copyright:** © 2024 by the authors. Submitted for open access publication under the terms and conditions of the Creative Commons Attribution (CC BY) license (<https://creativecommons.org/licenses/by/4.0/>)

**Keywords:** Diabetes, Alloxan, Metformin, *Eruca vesicaria*, ZnO NPs.

## 1. Introduction

Diabetes is one of the well-known and chronic diseases caused by the lack of insulin production or its non-use by cells, and the most famous types of diabetes are type 1 and type 2 diabetes. 537 million persons between the ages of 20 and 79 globally are predicted to have diabetes (10.5% of all adults in this age group). The 10th edition of the International Diabetes Report states that Southeast Asian nations, which currently account for 10.5% of the global population, have seen an increase in diabetes cases for at least 20 years [1]. Diabetes mellitus (DM) is a chronic illness characterized by persistently elevated blood sugar levels. It is the second greatest cause of years lived with disability globally and a major cause of death with high mortality rates. Long-term consequences such as nephropathy, retinopathy, and neuropathy that result in renal failure, visual impairment, blindness, and loss of peripheral sensations, respectively, are what make it so dangerous [2]. The primary cause of the two primary types of diabetes, type 1 and type 2, is a loss of functional beta cell mass. [3]. Diabetes is generally induced in laboratory animals as they play an effective role in understanding the causes of the disease and how to treat it [4]. The rat is widely used as a suitable laboratory animal to understand the metabolic steps and diseases involved in different diabetes [5]. One of the drugs used to induce diabetes in vitro and in laboratory rats is alloxan, which is a monohydrate monohydrate and a widely used chemical in the induction of diabetes that acts by damaging beta cells in the pancreas [6]. The chemical structure of alloxan is an organic compound with the formula  $OC(N(H)CO)2C(OH)2$ . It is classified as a pyrimidine derivative that exhibits a variety of biological activities and is commonly used as a beta-cytotoxic agent for the induction of type 1 diabetes [7].

One of the treatments used in the prevention of diabetes is the use of the drug metformin, which has the chemical structure dimethyl- It was first used as a clinical hypoglycaemic treatment in 1957 and was the number one treatment against type 2 diabetes (T2D). This metformin works through several cellular pathways, especially in the liver, intestines and muscles to treat insulin resistance and lower blood sugar without serious complications such as weight gain or the risk of hypoglycaemia. This drug is also used in controlling gestational diabetes in some countries due to its low cost and proven safety [8].

Due to the commercial production of nanoparticles and their numerous applications, biosynthesis has become a prominent field in nanotechnology. These particles have been produced using plant extracts, bacteria, and fungi because they include a range of active substances, such as proteins, carbohydrates, alkaloids, flavonoids, and others. [9]. According to Heer *et al.* [10], plant-mediated nanoparticle synthesis is superior to other bioprocesses because there are no problems with maintaining and preserving cell cultures, and low cost, environmental safety, ease of use, and low toxicity are some of the primary justifications for employing nanoparticle biosynthesis. Nanomaterials are synthesised using plant extracts from the *Eruca vesicaria* plant, and the leaf extract has been used to form spherical silver nanoparticles and zinc oxide nanoparticles [11, 12]. Compared to other treatments, ZnO nanoparticles have been used as an anti-diabetic treatment [13].

The aim of the study was to compare the effect of metformin and biosynthesised zinc oxide nanoparticles on liver tissue and some enzymes in male alloxan-induced diabetic rats.

## 2. Materials and Methods

### Ethical approval

The research was conducted at the Faculty of Education - Department of Biology at University of Samarra - Iraq according to the official approval on October 10, 2023, as the

ethical committee approved this project and the research did not conflict with any medical advice or prescription and the research was conducted following all internationally approved safety guidelines.

#### **Laboratory animals (white rats)**

This study was conducted on 35 male white rats (*Rattus rattus*) aged 8-12 weeks, whose weights ranged between 150-200 g. The animals were obtained from the animal house at the Faculty of Veterinary Medicine - University of Tikrit, and the appropriate conditions were created for them in terms of ventilation, lighting, nutrition and optimal temperature ranging between 25-30 ° C for the purpose of conducting the study and were left for a week before the experiment to adapt to the place.

#### **Biosynthesis of nanoparticles**

##### **Preparation of plant extract**

The aqueous extract of *Eruca vesicaria* leaves was prepared according to the method of Mofid *et al.* [14], by weighing 10 g of the dry powder of the plant and adding 100 ml of warm deionized water instead of distilled water and left for 24 hours, then placed on a shaker for 24 hours, then filtered using Whatman No.1 filter paper.

##### **Biosynthesis of Zinc Oxide Nanoparticles**

ZnO nanoparticles were synthesized according to the method described by Alharbi *et al.*, [15] with some modifications by adding 10 ml of previously prepared *E. vesicaria* leaf extract to 90 ml of Zn(NO<sub>3</sub>)<sub>2</sub>. 6H<sub>2</sub>O with a concentration of 1 mM and adjusting the pH to 7. It was then placed on a magnetic heated device for 35 minutes, then we notice the color change and the formation of a milky-colored precipitate, which indicates the synthesis of zinc oxide nanoparticles, the precipitate was collected and washed using deionized water several times, then the precipitate was dried in the oven and stored in order to complete the tests that confirm the formation of zinc oxide nanoparticles, including spectrophotometer examination (UV-vis), X-Ray Diffraction, and Transmission electron microscopy.

##### **Design of the animal experiment**

The experiment was designed according to Al-Murshidi *et al.* [16], where the animals were divided into five groups: The first group included non-diabetic animals and represented a negative control group, the second group included diabetic animals dosed with metformin and ZnO NPs 360+30 mg/kg body weight, the third group included diabetic animals dosed with metformin 360 mg/kg, the fourth group included diabetic animals dosed with alloxan only (160mg/kg), and the fifth group included diabetic animals dosed with ZnO NPs 30 mg/kg.

The experimental animals were dosed daily according to the concentration of each treatment for 30 days. After the end of the experimental period, the rats were sacrificed after being anaesthetised with chloroform and dissected by opening the abdominal cavity and blood was withdrawn by heart puncture, then some of the withdrawn blood was placed in clean glass tubes not containing anticoagulant to perform ALT and AST, as well as taking the liver organ and observing whether there are macroscopic changes and foci on it and then preserving it in 10% formalin for histological examinations, which included Dehydration, Clearing, Infiltration, Embedding, Sectioning, Staining, and Mounting. [17]. Aspartate transaminase (AST), and Alanine transaminase (ALT) concentration levels were estimated by ELIZA technique [18].

##### **Analysis of statistics**

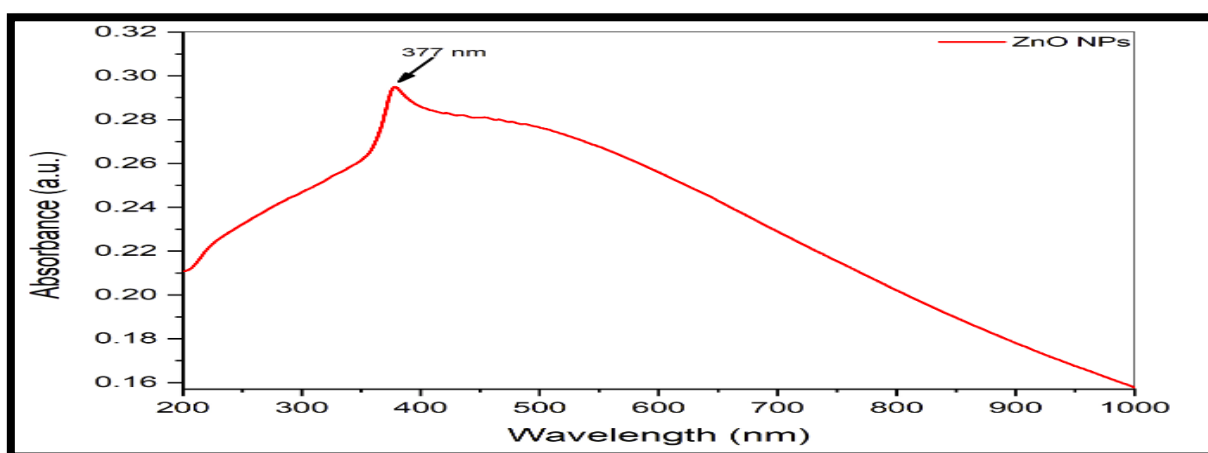
SPSS version 20.0 was used to analyze the data. Differences at  $P < 0.05$  were examined using ANOVA and descriptive statistics mean  $\pm$  standard error.

### 3. Results

#### Biosynthesis of Zinc Oxide Nanoparticles

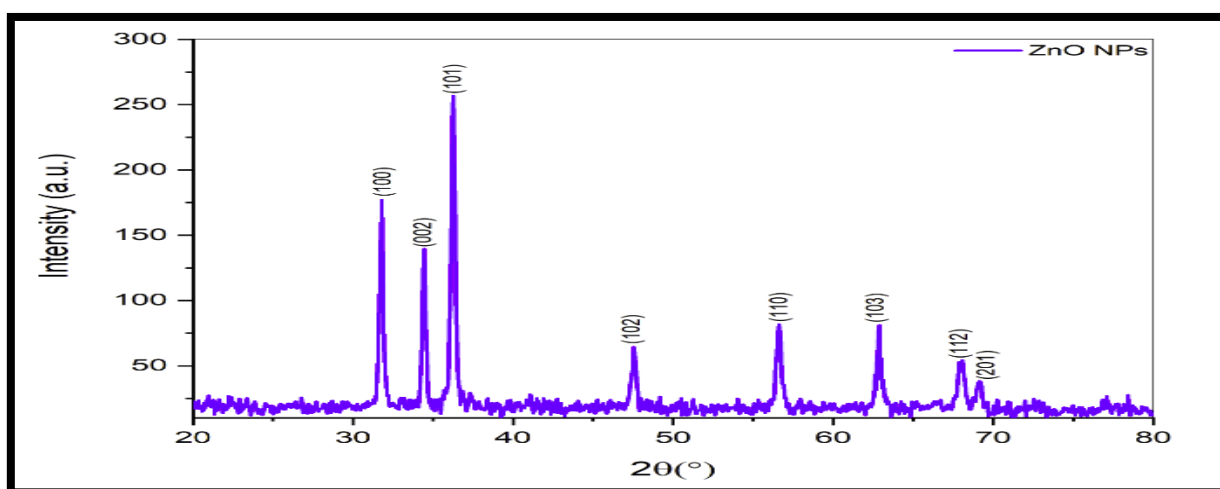
The results of biosynthesizing zinc oxide nanoparticles (green synthesis) using the aqueous extract of *Eruca vesicaria* leaves as a biological agent for the reduction of zinc nitrate  $Zn(NO_3)_2 \cdot 6H_2O$  to zinc oxide nanoparticles demonstrated the possibility of creating ZnO NPs biologically. The zinc nitrate solution's color changed from brown to yellow after the plant extract of watercress was added in the form of drops, and the color stabilized after 72 hours to a yellowish-white colors, indicating the reduction of zinc nitrate to zinc oxide nanoparticles.

Following the color shift, the UV/Vis spectrophotometer results of the biosynthesized nanoparticle solution showed an absorption peak at 377 nm wavelength. The presence of nanoparticles is indicated by the appearance of this peak between the specific wavelength of nano-sized particles, which ranges from 200 to 800 nm, as shown in Figure 1.



**Figure 1:** UV/Vis Spectrophotometer examination of biosynthesized ZnO NPs after 72 hours.

X-ray diffraction was also used to confirm the biosynthesis of ZnO NPs and reveal the size and crystalline quality of the particles. Eight distinct diffraction peaks appeared at  $2\theta$  values of 31.78, 34.25, 47.56, 62.84, 89.89, and 201.13, which matched 100, 002, 101, 110, 103, 112, and 201, respectively, with the standard chart under JCPDS card no: 36-1451. The XRD pattern from the figure displays peaks with narrow and strong diffraction, indicating that the biosynthesized ZnO NPs are crystalline.



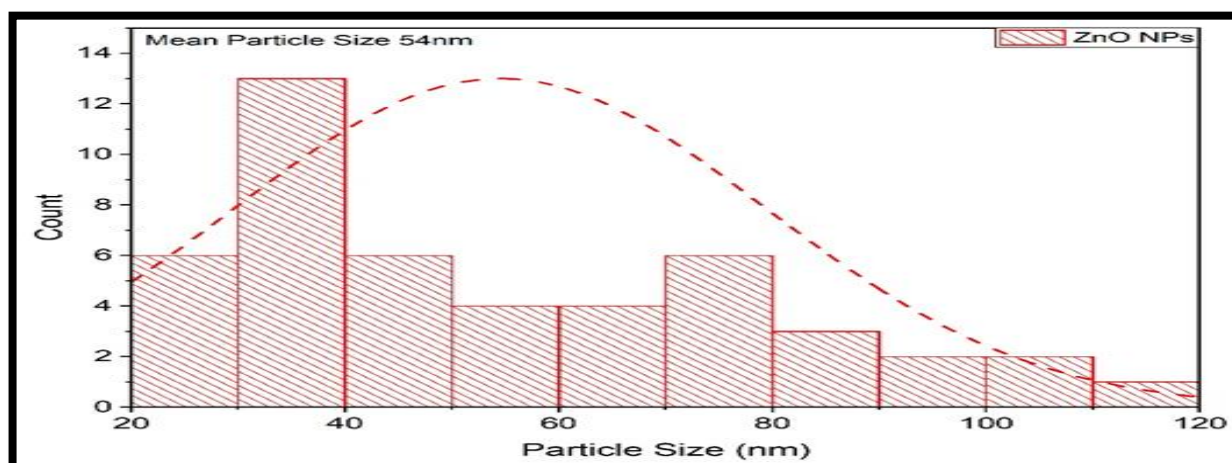
**Figure 2.** X-ray diffraction (XRD) spectrum of biosynthesized ZnO NPs.

The crystal size of the biosynthesized ZnO NPs is shown in Table 1, and the average crystal size of these particles is 31.21 nm.

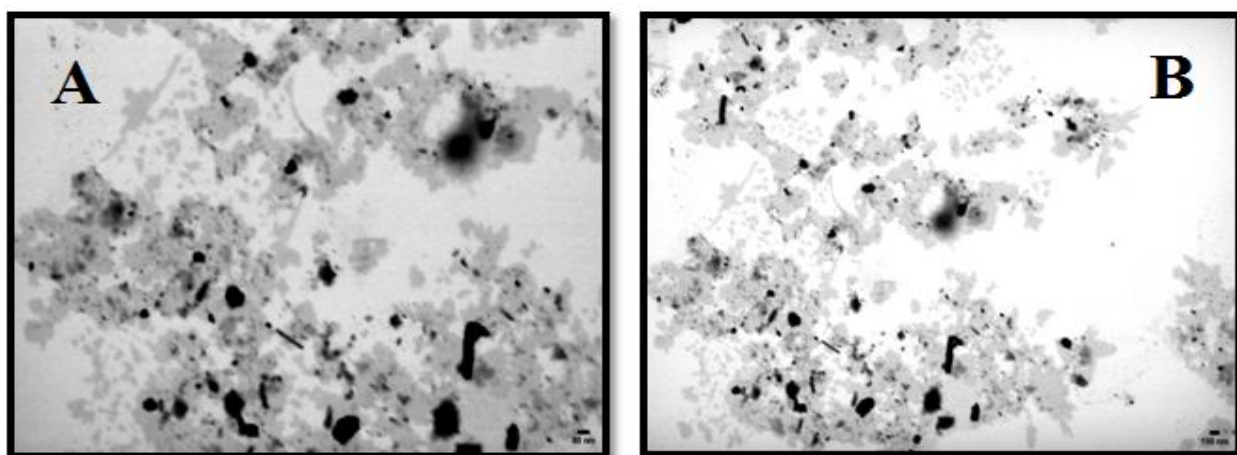
**Table.** Average crystalline size distribution of biosynthesized ZnO NPs in XRD

2 theta (degree)	hkl	FWHM (deg)	2 theta (Rad.)	FWHM (Rad)	D (nm)	Matched by
31.7846	100	0.22632	0.277	0.004	36.483	01-079-2205
34.41602	2	0.22632	0.300	0.004	36.733	
36.27203	101	0.22632	0.317	0.004	36.923	
47.56267	102	0.271584	0.415	0.005	31.953	
56.65527	110	0.316848	0.494	0.006	28.473	
62.84552	103	0.362112	0.548	0.006	25.699	
67.9956	112	0.45264	0.593	0.008	21.162	
69.13095	201	0.298515	0.603	0.005	32.305	
					31.216	

The size and appearance of ZnO NPs were assessed using transmission electron microscopy. The average size of ZnO NPs is 54 nm, as shown in Figure 3. The TEM results show that ZnO NPs have an essentially spherical form, and Figure 4 reveals that all of the particles appear to be the same size.



**Figure 3.** Size distribution of zinc oxide nanoparticles under TEM microscopy



**Figure 4.** Zinc oxide nanoparticles in a TEM microscope under power A - 80 nm , B - 150nm.

## A comparative study to evaluate the effect of metformin and biosynthesised nano-zinc in alloxan-induced diabetic rats

### Changes in liver enzymes ALT and AST

The results shown in Table 2 showed the results of measuring liver enzymes ALT and AST in experimental and control rats treated with different treatments. The results indicated that there were significant differences between treatments as the enzyme concentrations increased to  $137.75 \pm 26.21$  and  $162.25 \pm 4.99$  respectively in alloxan alone (sugar) treatment and decreased to  $70.50 \pm 80.12$  and  $156.25 \pm 65.52$  respectively in the combined treatment between alloxan, zinc oxide nanoparticles and metformin. On the other hand, ZnO nanoparticles showed a high and protective efficacy in maintaining and lowering enzyme levels when treated with alloxan alone (sugar). The enzyme concentrations of ZnO nanoparticles were  $37.75 \pm 25.49$  and  $54.52$ , respectively.  $75 \pm 25.49$  and  $54.00 \pm 18.24$ , respectively. The results of treatment of rats with metformin showed a decrease in ALT concentration to  $24.75 \pm 28.72$  and an increase in AST concentration to  $125.75 \pm 32.88$ .

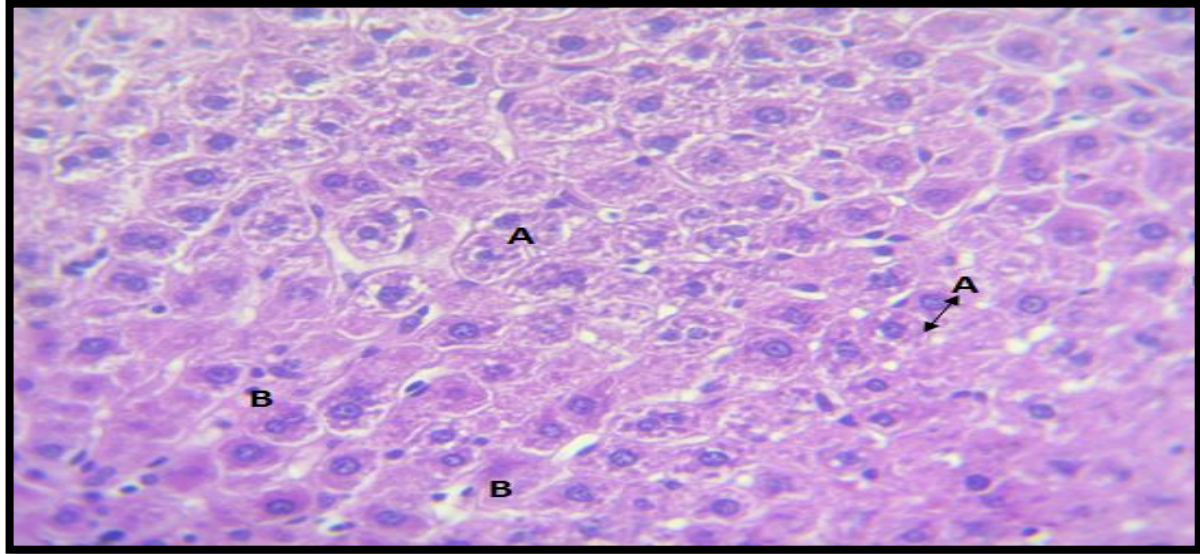
**Table 2.** Liver enzyme concentrations of ALT and AST in male rats.

Treatment	Concentration	NO.Rats	ALT	AST
Control	-	7	$36.50 \pm 45.12$ A	$54.00 \pm 18.24$ C
Sugar + ZnO NPs + Metformin	(30+360) mg/kg	7	$70.50 \pm 80.12$ B	$156.25 \pm 65.52$ Ab
Sugar + Metformin only	360mg/kg	7	$24.75 \pm 28.72$ C	$125.75 \pm 32.88$ B
Sugar (alloxan)	160mg/kg	7	$137.75 \pm 26.21$ D	$162.25 \pm 4.99$ A
Sugar + ZnO NPs	30mg/kg	7	$37.75 \pm 25.49$ Cd	$54.00 \pm 18.24$ C

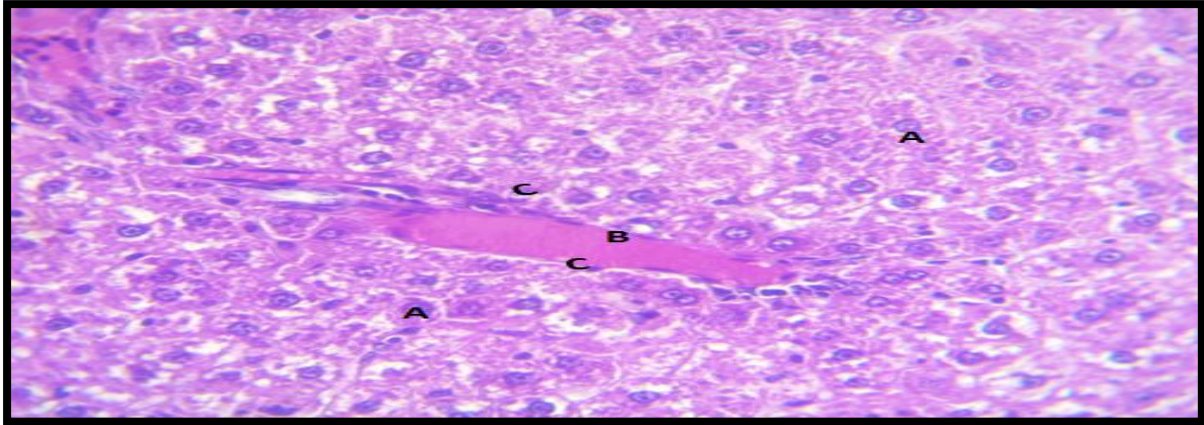
### Changes in liver tissue

The results shown in Figure 5 revealed healthy liver tissue in the control treatment, where the hepatocytes were shown in rows, and each cell contained one or two large-sized nuclei, and between the rows of hepatocytes there was a sinusoidal network containing Kupffer cells. Figure 6 showed the liver tissue after treatment with sugar, metformin and zinc oxide nanoparticles together, showing hypertrophy and degeneration of liver cells with nuclear enlargement, in addition to hemolysis in the central vein with white blood cells around the vein. Figure 7 shows the liver tissue with diabetes and metformin treatment. The figure shows the central vein in the liver devoid of blood and surrounded by rows of hepatocytes in a radial form and each cell appeared normal with a spherical nucleus and around the rows of cells, the network of blood sinusoids was found continuous with the vein at its periphery.

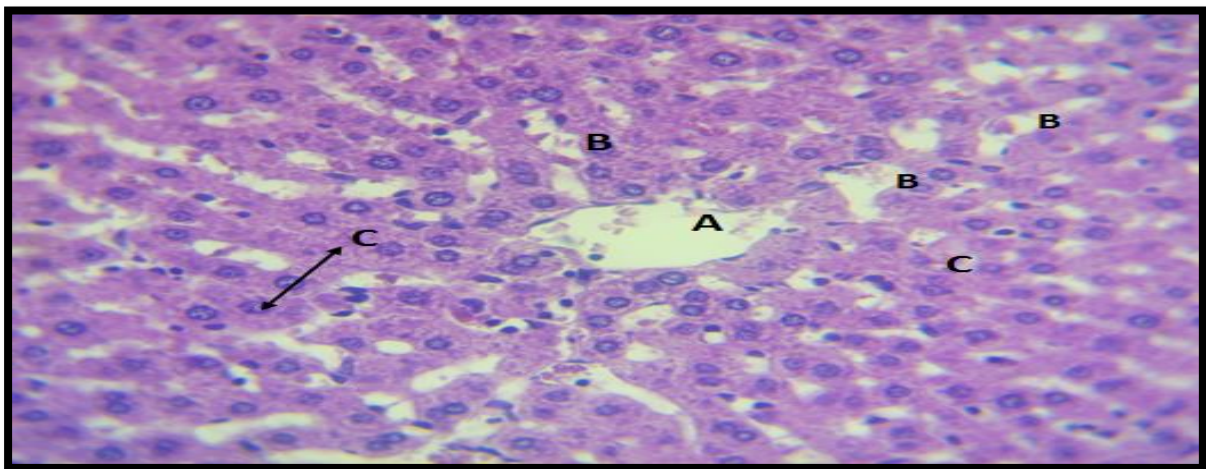
Figure 8 shows liver tissue with sugar treatment only (alloxan), in which the central vein contains hemolyzed blood and the blood sinusoids are connected to the wall and lumen of the vein at its edges, and these sinusoids are wide lumen and filled with Kupffer cells, most of which appeared enlarged and darkly pigmented, and many rows of liver cells appeared atrophied and other cells appeared in small groups. Figure 9 shows the liver tissue after ZnO treatment. The central vein in the middle of the hepatic lobe is wide lumen, devoid of blood and lined with endothelial squamous cells resting on the basement membrane. The liver tissue contained rows and aggregates of polygonal hepatocytes, and in the cytoplasm there appeared a thin foamy film around the cell nuclei, and the blood glomeruli appeared wide lumen and a network of vascular channels with many Kupffer cells, some of which were found to be hypertrophied.



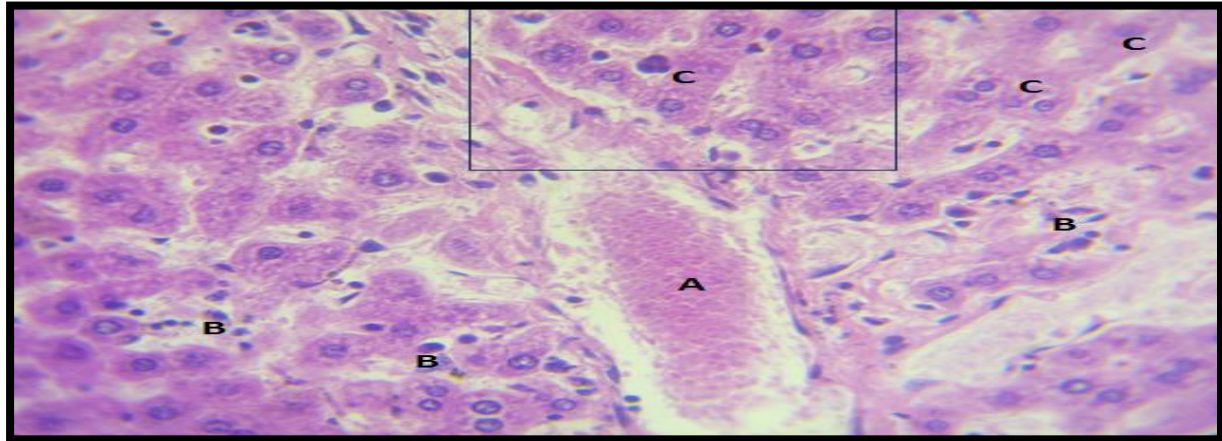
**Figure 5.** Healthy liver tissue in control treatment A- Polygonal hepatocytes with a central nucleus B- Glial network containing Kupffer cells (H&E 40X).



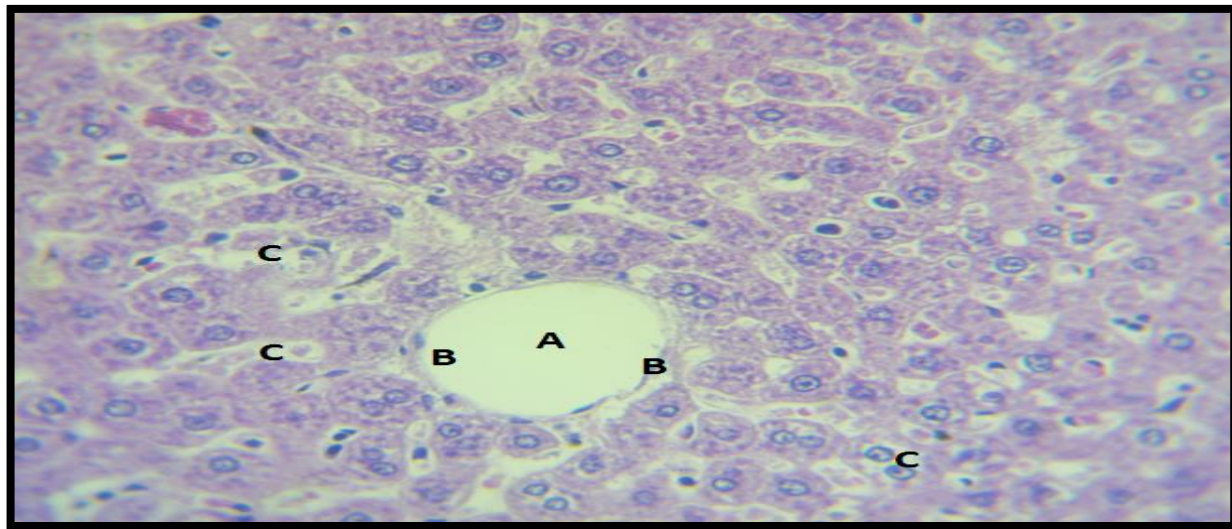
**Figure 6.** Liver histology after combined sugar + metformin + nano-zinc treatment A - Hyperplasia and degeneration of hepatocytes with nuclear hyperplasia B - Haemolysis in the central vein C - Perivascular leukocytes (H&E 40X).



**Figure 7.** Liver tissue after sugar + metformin treatment A - central vein B - sinusoids containing Kupffer's cells C - hepatocyte rows are planar and polygonal (H&E 40X).



**Figure 8.** Liver tissue after alloxan treatment A - central vein containing lysed blood B - dilated sinusoids filled with hyperplastic Kupffer cells C - hepatocyte atrophy and degeneration (H&E 40X).



**Figure 9.** Liver tissue after ZnO+ nanoparticle treatment A - The central vein is lined with squamous cells resting on the basement membrane B - Large blood sinusoids filled with enlarged Kupffer cells C - Hepatocytes with foamy vacuoles in the cytoplasm (H&E 40X).

#### 4. Discussion

The study's findings demonstrate the significance of plant extracts in the synthesis of nanomaterials and their safety, affordability, and lack of mutagenicity when compared to other biological methods represented by microorganisms. These findings are consistent with those of Awadelkareem *et al.*, [19] and Mohammed [20], who demonstrated the potential of using plant extracts from *Eruca vesicaria* as a safe, economical, and non-mutagenic method for the synthesis of nanoparticles. Zahoor *et al.* [21] demonstrated that plant extracts offer good coverage, stability, high stability, purity, and good crystalline qualities in the synthesis of ZnO nanoparticles.

When ZnO nanoparticles are synthesized using the green synthesis method, the color change process is consistent with Ifeanyichukwu *et al.* [22], who explained that the plant extract causes the zinc nitrate solution to turn off-white. The reason for this color change is because the plant extracts contain secondary metabolic compounds that can This is in line with the findings of Mohammed [20], and the Surface Plasmon phenomenon [23]. The X-RDY results of the biosynthesized ZnO nanoparticles are consistent with those of



Geremew *et al.* [24] which found eight peaks for zinc oxide particles synthesized from *Carya illinoensis* leaf extract.

Our results also found that ZnO nanoparticles can be used as an antidiabetic agent for alloxan-induced diabetes as it gave good results compared to metformin as it showed an improvement in liver enzyme level as well as protection of liver tissue and hepatocytes and this is in agreement with Hassan *et al.*, [25] who showed that ZnO NPs works to maintain liver enzymes and acts preventively to reduce elevated enzyme levels and improve liver function by significantly reducing serum AST and ALT activities. The same researcher also found that sugar (alloxan) treatment led to significantly higher enzyme levels. In agreement with Abd El-Aziz *et al.*[26] who found that zinc oxide nanoparticles reduced the levels of liver enzymes AST and ALT compared to alloxan-treated rats in which the serum levels of liver enzymes increased, the researchers also proved that zinc oxide nanoparticles can be used as an antidiabetic. The reason for this significant increase in diabetic liver enzymes is due to the effect of alloxan on hepatic injury that caused these enzymes to leak from the cytosol of hepatocytes into the bloodstream and this is consistent with the findings of Ghanbari *et al.*[27] and Alkattaby [28] As for metformin treatment, it is consistent with Naik *et al.*[29] who reported lower liver enzyme concentrations in metformin-treated rats and higher liver enzyme levels when treated with alloxan-induced diabetes.

The results of histological examination of the liver of diabetic rats were consistent with Afify *et al.*[30] who showed activation of Kupffer cells, vacuolation in the cytoplasm of hepatocytes, dilatation of sinusoids and some degenerative changes in hepatocytes. The results of histological examination of the liver of rats in control and alloxan-only treatment are consistent with the findings of Aslam *et al.*[31]who showed a normal histological structure in the liver in the normal control condition and alloxan treatment of rats showed pathological aberrations in the liver tissue such as infiltration of inflammatory cells, necrotic hepatocytes and expansion of blood sinusoids with vacuoles in hepatocytes in the liver.

The results of ZnO nanoparticles in diabetic rats are in agreement with Hassan *et al.*, [25] where they found that the induction of diabetes in rats causes severe pathological histopathological changes such as congestion of the central vein, hepatic sinusoidal bodies and activation of Kupffer cells compared to the normal histological structure of the liver from the normal central vein and hepatocytes arranged in the hepatic rows seen in the control group. The researchers also explained that the application of ZnO in diabetic rats revealed slight activation of Kupffer cells and the integrity of hepatocytes but did not agree with our study regarding hepatic vein congestion as they found congestion in the central vein while our results showed the integrity of the central vein in the liver.

The results of treatment of diabetic induced rats with zinc oxide nanoparticles are in agreement with Abdulmalek *et al.*, [32] who found that treatment of diabetic rats with ZnO nanoparticles resulted in the presence of central vein and hepatocyte structure appeared in regular rows with homogeneous cytoplasm, while the diabetic group showed marked dilatation of the dilated portal duct, bile duct, central vein and oedema Our study does not agree with the same researchers regarding the use of metformin, as they found that the use of metformin in diabetic rats showed marked dilatation and congestion in the portal tract and bile duct surrounded by fibrotic cells.

Hamza *et al.* [33] found that metformin preserved the central vein and reduced hepatocyte degeneration compared to the group of diabetic rats that showed blood congestion in the central vein with hepatocyte degeneration and dilation of the blood sinusoids. The results of zinc oxide nanoparticles are also consistent with Al-Murshidi *et al.*[16], who found that zinc oxide nanoparticles improve the mass of cells destroyed by sugar-induced damage in rats.

## 5. Conclusion

The results of our study found that plant extracts are effective in synthesising ZnO nanoparticles and that it is an easy, safe, environmentally friendly and inexpensive method. The study also found that biosynthesised ZnO nanoparticles can be used as an antidiabetic compared to metformin as ZnO nanoparticles showed protection of liver tissue and improvement in liver enzyme concentrations.

## REFERENCES

1. Kumar, A., Gangwar, R., Ahmad Zargar, A., Kumar, R., and Sharma, A. Prevalence of diabetes in India: A review of IDF diabetes atlas 10th edition. *Current diabetes reviews*, 2024, 20(1), 105-114.
2. Alzyoud, M., Alazaidah, R., Aljaidi, M., Samara, G., Qasem, M., Khalid, M., and Al-Shanableh, N. Diagnosing diabetes mellitus using machine learning techniques. *International Journal of Data and Network Science*, 2024, 8(1), 179-188.
3. Eizirik, D. L., Pasquali, L., and Cnop, M. Pancreatic  $\beta$ -cells in type 1 and type 2 diabetes mellitus: different pathways to failure. *Nature Reviews Endocrinology*, 2020, 16(7), 349-362.
4. Roep, B. O., & Atkinson, M. Animal models have little to teach us about type 1 diabetes: 1. In support of this proposal. *Diabetologia*, 2004, 47, 1650-1656.
5. Sharma, P., Garg, A., Garg, S., & Singh, V. Animal model used for experimental study of diabetes mellitus: an overview. *Asian J Biomat Res*, 2016, 2(4), 99-110.
6. Longkumer, S., Jamir, A., Kechu, M., Ezung, S., and Pankaj, P. P. Alloxan monohydrate induced diabetes: A comprehensive review. *Sciences*, 2020, 1(1), 1-9.
7. Nweze, C. C., Rasaq, N. O., and Istifanus, B. I. Ameliorating effect of *Agaricus bisponus* and *Pleurotus ostreatus* mixed diet on Alloxan-induced hyperglycemic rats. *Scientific African*, 7, 2020, e00209.
8. Bailey, C. J. Metformin: Therapeutic profile in the treatment of type 2 diabetes. *Diabetes, Obesity and Metabolism*, 2024, 26, 3-19.
9. Aritonang, H. F., Koleangan, H., and Wuntu, A. D. Synthesis of silver nanoparticles using aqueous extract of medicinal plants' (*Impatiens balsamina* and *Lantana camara*) fresh leaves and analysis of antimicrobial activity. *International journal of microbiology*, 2019,(1), 8642303.
10. Heer.A.S.K. Mansooria,S.M. and Chamria, N . Biosynthesis and characterization of ZnO nanoparticles using *Ficus religiosa* leaves extract. *World Journal of Pharmaceutical. Res*, 2017,6 (10): 818-826.
11. Veerasamy, R., Xin, T. Z., Gunasagaran, S., Xiang, T. F. W., Yang, E. F. C., Jeyakumar, N., and Dhanaraj, S. A. Biosynthesis of silver nanoparticles using mangosteen leaf extract and evaluation of their antimicrobial activities. *Journal of saudi chemical society*, 2011, 15(2), 113-120.
12. Alaraidh, I. A., Ibrahim, M. M., and El-Gaaly, G. A. Evaluation of green synthesis of Ag nanoparticles using *Eruca sativa* and *Spinacia oleracea* leaf extracts and their antimicrobial activity. 2013.
13. Hassanpour, S., Naghsh, N., Yazdanpanahi, N., and Talebian, N. Effect of zinc oxide nanocomposite and ginger extract on lipid profile, glucose, pancreatic tissue and expression of Gpx1 and Tnf- $\alpha$  genes in diabetic rat model. *Molecular Biology Reports*, 2024,51(1), 11.
14. Mofid, O., Mobayen, S., and Wong, W. K. Adaptive terminal sliding mode control for attitude and position tracking control of quadrotor UAVs in the existence of external disturbance. *IEEE access*, 2020,9, 3428-3440.
15. Alharbi, F. N., Abaker, Z. M., and Makawi, S. Z. A. Phytochemical Substances—Mediated Synthesis of Zinc Oxide Nanoparticles (ZnO NPS). *Inorganics*, 2023,11(8), 328.
16. Al-Murshidi, M. M., Khadhim, I. A., Al-Mafragy, H. S., and Al-Saily, H. M. Evaluation of the antidiabetic activity of zinc oxide and chromium oxide nanoparticles alone or in combination on the pancreas of alloxan-induced diabetes mellitus in male albino mice (*Mus musculus*). *Iraqi Journal of Veterinary Sciences*, 2023, 37(Supplement I-IV), 159-163.
17. Umrani, R. D., and Paknikar, K. M. Zinc oxide nanoparticles show antidiabetic activity in streptozotocin-induced Type 1 and 2 diabetic rats. *Nanomedicine*, 2014, 9(1), 89-104.

18. Alkaladi, A., Abdelazim, A. M., and Afifi, M. Antidiabetic activity of zinc oxide and silver nanoparticles on streptozotocin-induced diabetic rats. *International journal of molecular sciences*, 2014, 15(2).
19. Awadelkareem, A. M., Al-Shammari, E., Elkhalfifa, A. O., Adnan, M., Siddiqui, A. J., Patel, M., ... and Ashraf, S. A. Biosynthesized silver nanoparticles from *Eruca sativa* miller leaf extract exhibits antibacterial, antioxidant, anti-quorum-sensing, antibiofilm, and anti-metastatic activities. *Antibiotics*, 2022, 11(7), 853.
20. Mohammed, L. Y. Antioxidant activity and physico-chemical properties of green synthesized zinc oxide nanoparticles using *Eruca sativa* leaf extract. *Science Journal of University of Zakho*, 2023, 11(4), 581-591.
21. Zahoor, S., Sheraz, S., Shams, D. F., Rehman, G., Nayab, S., Shah, M. I. A., ... and Khan, W. Biosynthesis and Anti-inflammatory Activity of Zinc Oxide Nanoparticles Using Leaf Extract of *Senecio chrysanthemoides*. *BioMed research international*, 2023,(1),3280708.
22. Ifeanyichukwu, U. L., Fayemi, O. E., and Ateba, C. N. Green synthesis of zinc oxide nanoparticles from pomegranate (*Punica granatum*) extracts and characterization of their antibacterial activity. *Molecules*, 2020, 25(19), 4521.
23. Narayana, A., Bhat, S. A., Fathima, A., Lokesh, S. V., Surya, S. G., and Yelamaggad, C. V. Green and low-cost synthesis of zinc oxide nanoparticles and their application in transistor-based carbon monoxide sensing. *RSC advances*, 2020,10(23), 13532-13542.
24. Geremew, A., Carson, L., Woldesenbet, S., Wang, H., Reeves, S., Brooks Jr, N., ... and Peace, E. Effect of zinc oxide nanoparticles synthesized from *Carya illinoensis* leaf extract on growth and antioxidant properties of mustard (*Brassica juncea*). *Frontiers in Plant Science*, 2023, 14, 1108186.
25. Hassan, R. M., Elsayed, M., Kholief, T. E., Hassanen, N. H., Gafer, J. A., and Attia, Y. A. Mitigating effect of single or combined administration of nanoparticles of zinc oxide, chromium oxide, and selenium on genotoxicity and metabolic insult in fructose/streptozotocin diabetic rat model. *Environmental Science and Pollution Research*, 2021, 28, 48517-48534.
26. Abd El-Aziz, S. M., Raslan, M., Afify, M., Abdelmaksoud, M. D. E., & El-Nesr, K. A. Antidiabetic effects of curcumin/zinc oxide nanocomposite in streptozotocin-induced diabetic rats. In *IOP Conference Series: materials science and engineering*, 2021, (Vol. 1046, No. 1, p. 012023). IOP Publishing.
27. Ghanbari, E., Nejati, V., & Khazaei, M.. Improvement in serum biochemical alterations and oxidative stress of liver and pancreas following use of royal jelly in streptozotocin-induced diabetic rats. *Cell Journal (Yakhteh)*, 2016, 18(3), 362.
28. Albarakaty, F. M., Alzaban, M. I., Alharbi, N. K., Bagrwan, F. S., Abd El-Aziz, A. R., & Mahmoud, M. A. Zinc oxide nanoparticles, biosynthesis, characterization and their potent photocatalytic degradation, and antioxidant activities. *Journal of King Saud University-Science*, 2023, 35(1), 102434.
29. Naik, A., Adeyemi, S. B., Vyas, B., & Krishnamurthy, R. Effect of co-administration of metformin and extracts of *Costus pictus* D. Don leaves on alloxan-induced diabetes in rats. *Journal of Traditional and Complementary Medicine*, 2022, 12(3), 269-280.
30. Afify, M., Samy, N., Hafez, N. A., Alazzouni, A. S., Mahdy, E. S., El Mezayen, H. A. E. M., and Kelany, M. M. Evaluation of zinc-oxide nanoparticles effect on treatment of diabetes in streptozotocin-induced diabetic rats. *Egyptian Journal of Chemistry*, 2019, 62(10), 1771-1783.
31. Aslam, B., Hussain, A., Sindhu, Z. U. D., Nigar, S., Jan, I. U., Alrefaei, A. F., ... & Khan, R. U. Polyphenols-rich polyherbal mixture attenuates hepatorenal impairment, dyslipidaemia, oxidative stress and inflammation in alloxan-induced diabetic rats. *Journal of Applied Animal Research*, 2023, 51(1), 515-523.
32. Abdulmalek, S., Nasef, M., Awad, D., & Balbaa, M. Protective effect of natural antioxidant, curcumin nanoparticles, and zinc oxide nanoparticles against type 2 diabetes-promoted hippocampal neurotoxicity in rats. *Pharmaceutics*, 2021, 13(11), 1937.
33. Hamza, M., Mujhtaba, H. A., Aslam, A., Suhail, Z., Mehmood, K., & Salamat, A. Hepatoprotective Role of Aqueous Extract of Kasni Seeds in Alloxan-Induced Diabetic Mice: Hepatoprotective Effects of Kasni Seeds. *Journal of Health and Rehabilitation Research*, 2024 4(3), 1-5.