

The Nature of the Blood Flow in the Venous Plexus System in Patients with Lumbosacral Radiculitis

1. Djurabekova Aziza Taxirovna
2. Shmirina Ksenia Vladimirovna
3. Vyazikova Natalya Fyodorvna
4. Shukurov Shoxrux

Received 17th May 2021,
Accepted 18th June 2021,
Online 1st Aug 2021

¹DsC, Professor, ^{2,3}PhD, Assistant,
⁴Master

¹²³⁴ Department of Neurology and
Neurosurgery, Samarkand State
Medical Institute, Samarkand,
Uzbekistan

ABSTRACT: The defeat of the lumbosacral spine is one of the most common pathologies leading to the development of persistent pain syndrome. There is a decrease in the quality of life, disability, which in turn leads to economic losses. Until now, there is no consensus on the pathogenesis of radiculopathies, which makes it difficult to conduct pathogenetically based treatment. There are many theories of the onset of pain syndrome in vertebrogenic radiculitis, but recently the change in hemodynamics in its formation is of interest. The article discusses the nature of vascular blood flow in the venous plexus system in patients with lumbosacral radiculitis. A decrease in the blood flow velocity in the system of the epidural-venous plexus and radicular veins in the area of vertebral segments lesions was revealed, which implies the addition of drugs that improve blood flow in the vessels of the spinal column structures to the complex treatment of this category of patients.

Keywords: lumbosacral radiculitis, clinic, MRI, ultrasound of the vessels of the lower extremities

Relevance. In recent years, literary and scientific sources attach importance to the pathomechanical formation of lumbosacral radiculopathy [1,3,5,8]. The main factors influencing the onset of a degenerative dystrophic process can be divided into factors of vertebrogenic and non-vertebral origin [1,2,6,7,12,14,18,19,21]. Vertebrogenic genesis is associated with compression-spondylogenic, autoimmune inflammatory process. Nonvertebrogenic genesis is the result of muscle-neural maladjustment [6,9,10,11,18,19,21].

Widespread and poorly understood, is the role of vascular factor on the clinical signs of lumbar-cruciate radiculitis [13,16,20]. The importance of compression-vascular changes in the formation of neurovascular disorders in this pathology remains of interest. Novoseltsev S.V. (2015) raises the issue of hemodynamics in patients with lumbosacral syndrome, explaining the pathological changes in ischemisation against the background of venous stasis and microcirculation disorders, which ultimately lead to the local development of epiduritis. In turn, a decrease in blood flow in a certain area and in the venous plexus system leads to the development of neuroradicular phenomena [13,15,16,17,20].

The use of Doppler mapping in the veins of the epidural plexus shows the intensity of the energy signal and the rate of blood flow, thus, this diagnostic method is reliable, non-invasive, convenient to use and effective for solving a tactical approach to treatment.

Target. To study the nature of vascular blood flow in the venous plexus system in patients with lumbosacral radiculitis.

Materials and research methods. 60 patients with lumbosacral radiculitis were examined on the basis of the Department of Neurology and Neurosurgery of the 1-Clinic SamMI for the period 2019-2021. The control group consisted of relatively healthy - the number of 35 people, and was composed on the basis of outpatient observation of people without pathological changes in the spine. The patient's age was on average 25 to 55 years (39.8 ± 2.38 years). The exclusion criteria were: heart disease, diabetes mellitus, autoimmune diseases.

The patients underwent a comprehensive examination: including (standard, traditional) clinical and neurological examination, taking into account the vertebro-neurological symptoms. Additional research methods: biochemical blood test (according to the standard); assessment of the severity of pain on an analogue scale VAS, MRI study in dynamics, ultrasound (ultrasound) (using power Doppler) of the vessels of the epidural venous plexuses and radicular veins of the lower extremities.

Statistical processing was carried out using Spearman analysis on an individual computer.

Research results. The examination of patients was carried out upon admission to the hospital, according to standard neurological signs, with a detailed study of the vertebro-neurological indicator for the diagnosis.

It was very important to determine the type of disease course, frequency, duration of the disease, stage of the disease. Among all patients with lumbosacral radiculopathy, compression of the L4 root was detected in only one patient; L5 - found in 7 patients. The highest isolated compression ratio was at the S1 level, over 40%. The duration of the disease was from 5 to 10 years.

Pain syndrome is ambiguous, radiation of pain depended on the level of injury, and corresponded to many literature data. Thus, in patients with the level of root lesion L3 – L4, the patients experienced pain on the surface of the thigh and in the knee (on the identical side) 35%; sometimes the pain began in the groin area, which made it difficult for a long time to make a correct diagnosis.

Sensory impairment, respectively, was in the form of hyperesthesia in the above-described areas. In patients with lesions at the L5 level, pain radiated along the edge of the thigh and on the surface of the lower leg, in 90% of cases. Patients could not stand on their heels for a long time (on the identical side), the sensitivity was impaired by the type of hypesthesia.

The most frequent lesion of the root at the S1 level, in such patients usually the pain began with a sharp "lumbago" in the lumbar region and buttocks 90%. Clinical examination revealed the absence of the Achilles reflex in these patients, and these same patients found it difficult to stand on their toes (on the identical side). In this category of patients, it was found difficulty in walking, a "sparing" gait with external rotation and abduction of the leg.

The neurovascular factor of impairment proves such symptoms as increased pain in the cold, a decrease in pain from thermal procedures. Pallor of the skin, brittle nails indicate a vegetative disorder, expansion of the saphenous veins.

In many cases, a combination of disorders of the arteriovenous system was noted, in which the pain was bursting in nature and decreased with changes in the patient's posture (Fig. 1).

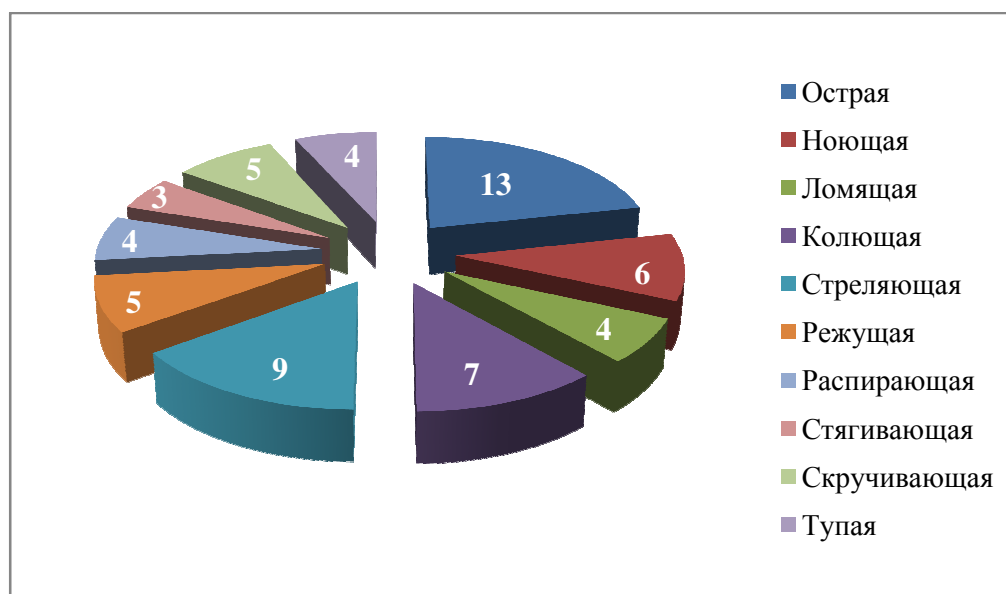


Fig. 1. The nature of pain in patients with lumbosacral radiculopathy.

Thus, a symptom of mixed-type neurovascular disorders occurred in almost all examined patients, and most importantly, the symptoms tended to increase, depending on the duration of pain and the formation of chronicity of the process.

The gold standard of examination at the present stage is the method of magnetic resonance imaging (MRI), in the study, all patients underwent this method (in some cases over time).

The examination result, a change in the lumbosacral region in all patients in the form of degenerative-dystrophic disorders characteristic of osteochondrosis, protrusion and hernia at the levels L4-L5, L5-S1, in particular protrusion in 70%, the rest of the percentage of herniated intervertebral discs. In 40% of patients, a combination of protrusion and herniated intervertebral discs, mainly median, with mild laterization, ranging in size from 6.0 to 9.0 mm, was found.

To confirm the neurovascular damage factor, an ultrasound examination (US) of the vessels of the lower extremities was carried out, both in the examined patients and in the comparison group (healthy individuals) (Table 1).

Table 1
Duplex scanning of lower limb arteries in examined patients

Duplex Scan Performance		Main group (n = 60)	
		Sore leg (M ± SD)	Healthy leg (M ± SD)
Common femoral artery	PSS (cm / sec)	92.9 ± 9.3	92.7 ± 9.4
	CDS (cm / sec)	14.8 ± 1.6	14.7 ± 1.7
	IR (units)	0.84 ± 0.09	0.85 ± 0.08
Popliteal artery	PSS (cm / sec)	70.9 ± 7.7	71.1 ± 7.6
	CDS (cm / sec)	12.9 ± 1.3	12.6 ± 1.4
	IR (units)	0.82 ± 0.09	0.82 ± 0.08
Posterior tibial artery	PSS (cm / sec)	45.1 ± 4.6	59.9 ± 5.8
	CDS (cm / sec)	9.1 ± 1.4	16.3 ± 1.7
	IR (units)	0.76 ± 0.09	0.77 ± 0.09
Dorsal artery of the foot	PSS (cm / sec)	36.4 ± 4.2	49.8 ± 5.4
	CDS (cm / sec)	7.9 ± 1.5	12.9 ± 1.7
	IR (units)	0.75 ± 0.07	0.75 ± 0.08

Vascular ultrasound showed a decrease in blood flow velocity in the affected areas. At the same time, in the radicular vein system, a decrease in blood flow was also noted in comparison with the healthy group (Table 2-3).

Table 2

Blood flow velocity in the veins of the epidural venous plexuses in the examined patients

Localization of the level of research of blood flow velocity	Control (n = 35)		Main group (n = 60)	
	On right (M ± SD) (cm / sec)	Left (M ± SD) (cm / sec)	Affected side (M ± SD) (cm / sec)	Healthy side (M ± SD) (cm / sec)
L4-L5	18.1 ± 2.4	18.1 ± 2.4	12.1 ± 1.2	18.1 ± 2.4
L5-S1	18.4 ± 3.2	18.4 ± 3.2	11.01 ± 1.1	18.1 ± 3.2

Table 3

Blood flow velocity in the radicular veins in the examined patients

Localization of the level of research of blood flow velocity	The control (n = 35)		Main group (n = 60)	
	On right (M ± SD) (cm / sec)	Left (M ± SD) (cm / sec)	Affected side (M ± SD) (cm / sec)	Healthy side (M ± SD) (cm / sec)
L4-L5	18.1 ± 2.4	18.1 ± 2.4	10.1 ± 1.0	18.0 ± 2.4
L5-S1	18.4 ± 3.2	18.4 ± 3.2	11.1 ± 0.1	18.2 ± 3.4

Discussion. The development of the degenerative process, and as a consequence, the limitation of venous lymphatic outflow, leads to venous stasis in the lower spine. The whole process ultimately contributes to the development of ischemia of the structures of the spine.

Thus, at the level of the lesion, a violation of microhemodynamics in the systems of the venous plexus and at the level of the radicular veins is found, evidence of this decrease in the velocity of blood flow in the vessels, which in turn gradually disrupts the trophism and reduces the functional ability of the spinal nerves.

The data obtained allow a new look at the issues of treatment, including a complex of therapy, drugs that improve the blood flow of the spinal column.

Conclusions. The result of clinical-differential diagnosis of lumbosacral radiculopathy requires careful and cumulative observation of the dynamics of the development of the disease.

To confirm the diagnosis of clinical-neurological and vertebro-neurological, to study the level of the degenerative-dystrophic process in terms of severity, it is necessary to conduct magnetic resonance imaging in dynamics.

The method of ultrasound examination proved a decrease in the blood flow velocity in the system of the epidural-venous plexus and radicular veins in the area of the lesion of the vertebral segments.

The mechanism of disturbance of microhemodynamics involves the addition of drugs to the complex treatment of this category of patients, which improve blood flow in the vessels of the structures of the spinal column.

Literature.

1. Asadova F.D., Dzhurabekova A.T., Shmyrina K.V., Safarova E.K. (2019) Clinical and neurological symptoms and treatment of lumbar dorsopathies. *Achievements of science and education*, 13 (54), 93-97
2. Visilo A.D., Visilo T.L., Chechenin A.G., Polukarova E.A. (2015) Autonomic and affective dysfunction in acute and chronic lumbosacral pain. *Medicine in Kuzbass*, 2 (special issue), 4-7
3. Zinovieva O.E., Barinov A.N. (2018) Pathogenetic treatment of non-specific back pain. *Medical Council*, 9, 25-28
4. Novoseltsev S.V. (2013) *Clinical osteopathy. Reflex Techniques SPb. : FOLIANT*
5. Maksimov Yu.N., Khaibullina D.Kh., Devlikamova F.I. (2020) Evaluation of the effectiveness of a complex preparation of B vitamins in combination therapy of lumbar radiculopathies. *Medical Council*, 21, 42-47. doi: 10.21518 / 2079-701X-2020-21-42-47
6. Pizova N.V. (2020) Back pain. *Medical Council*, 21, 70-77, doi: 10.21518 / 2079-701X-2020-21-70-77.
7. Umirova S.M., Mavlyanova ZF, Sabirova Sh.B. (2019) Rehabilitation measures for protrusion of intervertebral discs of the lumbar spine in athletes engaged in various types of martial arts. *Achievements of science and education*, 12 (53), 68-71
8. Khakimova S.Z., Mamurova I.N., Samiev A.S. (2019) The clinical role of neurobrucellosis among patients with chronic radiculopathy, 10 (49), 65-67
9. Shmyrina K.V. (2011) The quality of life of patients with chronic vertebral back pain and issues of rationalization of treatment tactics. Abstract of thesis. Cand. dis.
10. Shmyrina K.V., Vyazikova N.F., Dzhurabekova A.T., Chorshanbiev I. (2016) Experience of using gabagamma in the treatment of chronic nonspecific pain in the lower back. *Medicine of Alma Ata*, 7/69, 56-60.
11. Shmyrina K.V., Dzhurabekova A.T., Vyazikova N.F., Beknazarov N.N. (2016) Optimization of the treatment of osteochondrosis of the lumbosacral spine. *Medicine of Alma Ata*, 7/69, 62-66.
12. Balagué, Federico, et al. (2012) Non-specific low back pain. *The Lancet*, 379.9814: 482-491. Level of evidence 1A
13. Bozkurt, Gökhan MD; İl, Barbaros MD; Akbay, Atilla MD, PhD; Türk, Cezmi ağr MD; Palaoğlu, Selçuk MD, PhD (2006) Intractable Radicular and Low Back Pain Secondary Inferior Vena Cava Stenosis Associated With Budd-Chiari Syndrome: Endovascular Treatment With Cava Stenting: Case Report and Review of the Literature, *Spine*, Volume 31, Issue 12, E383 -E386 doi: 10.1097 / 01.brs.0000219516.54500.97
14. Chenot JF, Greitemann B, Kladny B, Petzke F, Pflingsten M, Schorr SG. (2017) Non-Specific Low Back Pain. *Dtsch Arztebl Int.* Dec 25, 114 (51-52), 883-890. doi: 10.3238 / arztebl.2017.0883. PMID: 29321099; PMCID: PMC5769319.
15. Djurabekova A.T., Shmyrina K.V., Asadova F.D., Vyazikova N.F. (2021) The effectiveness of angioprotective treatment in patient with lumbar-sacral radiculopathy. *European Journal of Molecular & Clinical Medicine*, Volume 08, Issue 02, 815-819
16. Dudeck, Oliver MD; Zeile, Martin MD; Poellinger, Alexander MD; Kluhs, Lothar MD; Ludwig, Wolf-Dieter MD; Hamm, Bernd MD (2007) Epidural Venous Enlargements Presenting With Intractable Lower Back Pain and Sciatica in a Patient With Absence of the Inferior Vena

Cava and Bilateral Deep Venous Thrombosis, Spine: November 1, Volume 32, Issue 23, E688-E691 doi : 10.1097 / BRS.0b013e318158cf94

17. Espahbodi, Shima PhD; Doré, Caroline J. BSc; Humphries, Keith N. MSc; Hughes, Sean P. F. MS, (2013) FRCS Color Doppler Ultrasonography of Lumbar Artery Blood Flow in Patients With Low Back Pain, Spine: February 15, Volume 38, Issue 4, E230-E236 doi: 10.1097 / BRS.0b013e31827ecd6e
18. Maher C, Underwood M, Buchbinder R. (2017) Non-specific low back pain. Lancet. 389 (10070), 736-747. doi: 10.1016 / S0140-6736 (16) 30970-9. Epub 2016 Oct 11. PMID: 27745712.
19. Masatoshi T, Noriko Y, Hiroshi H at al. (2015) The association of combination of disc degeneration, end plate signal change, and Schmorl node with low back pain in a large population study: the Wakayama Spine Study, Spine J., 15 (4), 622-8. doi: 10.1016 / j.spinee.2014.11.012. Epub 2014 Nov 27.
20. Paksoy, Yahya MD; Gormus, Niyazi MD (2004) Epidural Venous Plexus Enlargements Presenting With Radiculopathy and Back Pain in Patients With Inferior Vena Cava Obstruction or Occlusion, Spine, Volume 29, Issue 21, 2419-2424 doi: 10.1097 / 01.brs.0000144354.36449.2f
21. Will JS, Bury DC, Miller JA. (2018) Mechanical Low Back Pain. Am Fam Physician. 98 (7), 421-428. PMID: 30252425.