

Indicators of Postnatal Ontogenetic Development of the Mucous Membrane of the Pulmonary Bronchi in Young Children during Breastfeeding

1. Kamolova Gulirano Bahridin qizi
2. Sadikova Zumrat Shavkatovna
3. Sultonov Ravshan Komiljonovich

Received 2nd Sep 2022,
Accepted 3rd Oct 2022,
Online 5th Nov 2022

^{1,2,3} Department of anatomy, Clinical
Anatomy, Tashkent Medical Academy,
Uzbekistan

Abstract: This article aims to conduct an analysis of the dynamics of indicators of postnatal ontogenetic development of the mucous membrane of the pulmonary bronchi in young children during breastfeeding. The examination was carried out at the Republican Center for pathological anatomy on the corpse of infants of the nursing period, from 2021 to 2022.

It was found that the wall of the pulmonary fragments of the head bronchi in a one-month period turns from a varoncasic form into a cylindrical shape, the covering epithelium from a multi-row, tortuous state into a single-layer smooth structure, the private plate from a multicellular non-formed state into a fibrous-structured connective tissue, the mountain peoples from a flat and.

Key words: baby, bronx, postnatal ontogenesis, general histological, histochemical, covering epithelium, cartilage floor.

Relevance of the problem: The search for new approaches to the etiopathogenetic treatment of bronchoobstructive diseases in pediatric practice is one of the most important tasks, and it is an urgent problem in children's pulmonology. The need to know the main stages of the formation of organs in the antenatal period of ontogenesis and the clarification of the factors associated with them serve as a reliable tool for the search for ways of occurrence of congenital disorders and defects. [1]

American Anatomy Association when they conducted research on the examination of pulmonary ganglia in the human fetus (Cho KH, Kim JH, Jin ZW, Abe H, Murakami G, Rodríguez-Vázquez JF 2019). The authors carried out immunological attachment of intrauterine nerves with the use of 17 human fetuses at 14-18 and 28-34 weeks. [2-3]

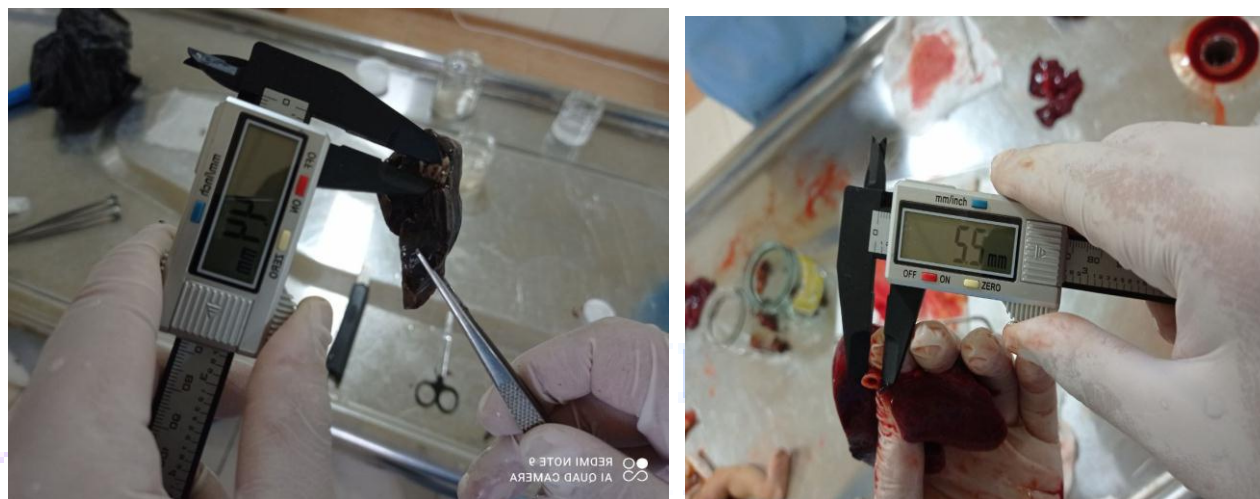In recent years, the level of air pollution has increased significantly, and there is much evidence that exposure to tiny damaging particles can lead to negative consequences of breathing. the impact of environmental impact on health can affect air pollution during the prenatal period, especially pulmonary bronchi organogenesis. [4-5-6].

The purpose of the study: To study the dynamics of indicators of postnatal ontogenetic development of the mucous membrane of the pulmonary bronchi in young children during breastfeeding.

Research materials and methods: the examination was carried out at the Republican Center for pathological anatomy on the corpse of infants of the nursing period, which came 2021-2022. In dead children, the lungs were studied in the corpse of children who died mainly as a result of congenital heart defects and other causes that did not have diseases in the bronchi.

The examination material was obtained from the following parts of the lungs: that is, it was studied by opening the right and left pulmonary bronchi from the split bronchi to the terminal bronchi. In our study, instrumental (using the shtangen circus), general histological, histochemical examination methods were used.

Figure 1. Infant lungs, 3-month period. Obtaining a share of extrapulmonary bronchi using a stangentsirkul.



Research results:

One month period. Up to the 1-month period of newborns, the bronchi of the lung fragments appear varuncally, the length is 3.7 ± 0.8 cm, the width of the cavity is on average 0.7 ± 0.1 cm. The wall was relatively soft, that is, the Taiga peoples were poorly developed, thin and soft. It was found that the taiga peoples had one whole structure broken down and consisted of several fragments.

It was found that on the mucous membrane, adjacent to the private plate, a smooth muscle cell junction is located. It was found that the mucous membrane consists of unformed connective tissue, which is thin, light-colored, with very few fibers and cells subject to edema. In the mucous membrane, serous-mucous glands are located, in relation to the trachea, there were few of them and the presence of an unspoiled structure.

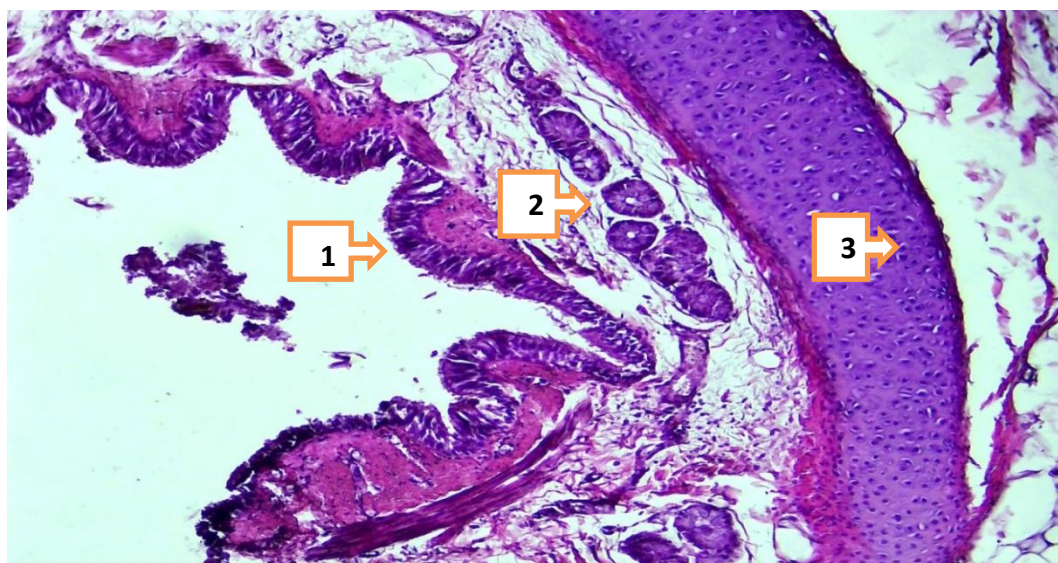


Figure 2. lung fragments bronchi, 1 month period. The mucous membrane folds are relatively small(1), the mucous membrane is thin, there are few tissue structures(2), the cartilage ring is multicellular (3). Paint: G-E. Ass: 10x40.

3-month period. During this period of babies, it was found that the bronchi of the lung fragments turned into a tubular shape, slightly elongated in length, that is, on average 4.2 ± 0.9 cm, and the width of the cavity was on average 0.8 ± 0.2 cm. The thinness of the wall is preserved, it was found that the Taiga peoples are still poorly developed, the wall is thin and soft. It was found that the taiga peoples consist of several fragments. On the mucous membrane, it was observed that the smooth muscle cells adjacent to the private plate slightly thickened. It was found that the number of serous-mucous glands in the mucous membrane increased by 2 times and increased swelling.

6 month period. By this period of examination, it was found that the inner bronchi of the lung fragments retained a tubular shape, slightly elongated in length, that is, on average 4.4 ± 0.9 cm, and the width of the cavity was on average 0.26 ± 0.2 cm. The thinness of the wall is preserved, it was found that the Taiga peoples found a relatively Tacos, The Wall was thin and soft. It was found that the taiga peoples consist of several fragments. It was found that the mucous membrane folds were lost, the smoothed surface was covered with a single-layer multi-row cylindrical epithelium, in some areas the epithelial height decreased and deposits appeared. Among the covering epithelium, it was found that the cells of the packaging increased slightly compared to the previous period. It was found that the basal membrane and the private plate with connective tissue consist of dense fibers, the cell is relatively small and sparsely located. It was observed that the junction of smooth muscle cells adjacent to the private plate is slightly compacted. It was found that the number of serous-mucous glands increased in the mucous membrane and increased swelling.

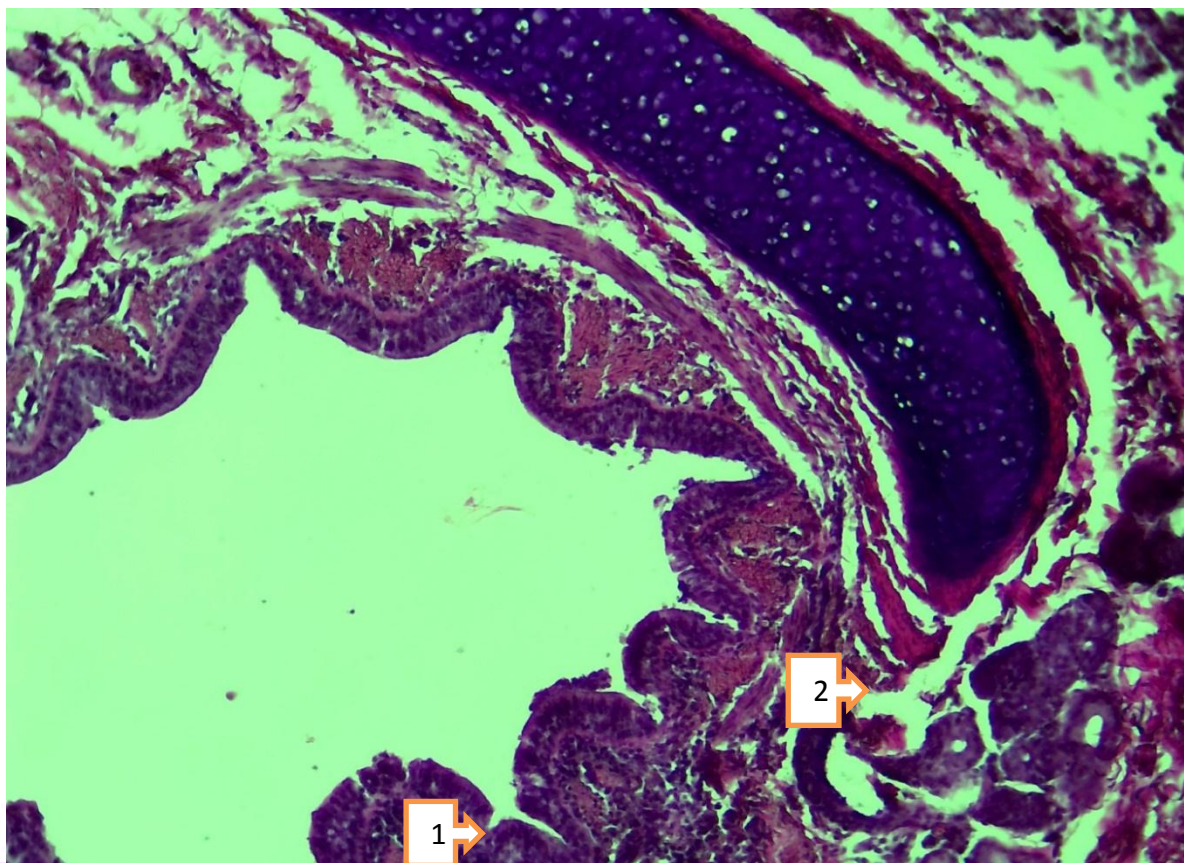


Figure 2. Slice-inside bronchiola, 6-month period. The covering epithelium is cylindrical(1), the private plate (2) is rich in fibers. Paint: G-E. Ass: 10x40.

Conclusions:

It was confirmed that the wall of the pulmonary fragments of the head bronchi turns from a funnel-shaped form to a cylindrical shape in a one-month period, the covering epithelium from a multi-row, twisted state to a single-layer smooth structure, the private plate from a multicellular unformed state to a fibrous-structured connective tissue, the mountain peoples from a flat and.

It was found that the layers of the bronchiola wall inside the fragments formed from a not fully formed state during the one-month period of the babies and found themselves in evolution, the covering epithelium was twisted, the qadohsial cells were smoothed from a low state, qadohsial cells became multi-state, the private plate was formed from a swollen, unformed connective tissue with fibers.

Used literature:

1. Сатвалдиев Р. Х, Эшниязов Д. Д, “Ўзбекистон статистика ахборотномаси” илмий электрон журнали.2019 йил, 2-сон.
2. Самсыгина Г.А, Козлова Л.В. Пневмония. Педиатрия. Национальное руководство.М:Геотар-Медиа, 2009; 119-139.
3. Харченко В.В, Мантулина Л.А, Никишина Е.И, Бахмет А.А, Ключкова С.В. Состояние слизистой оболочки трахеобронхиального дерева в норме у людей зрелого возраста. Курский научно-практический вестник "Человек и его здоровье". – 2016. – № 3.

4. Cindy T. McEvoy, MD, MCR, Eliot R. Spindel, MD, PhD. "Pulmonary Effects of Maternal Smoking on the Fetus and Child: Effects on Lung Development, Respiratory Morbidities, and Life Long Lung Health". Paediatr Respir Rev. 2017 January 21.
5. Insa Korten, Kathryn Ramsey, Philipp Latzin. Air pollution during pregnancy and lung development in the child. Paediatric Respiratory Reviews 21 (2017) 38–46.
6. Ключкова С.В., Акматов Т.А., Алексеева Н.Т., Никитюк Д.Б. Бронхиальные железы: возрастные, регионарные и индивидуальные особенности строения. // Журнал анатомии и гистопатологии. 2021;10(3):47-52.

