

Choice Of A Transplantation Material For Stabilization Of The Neck Spine

¹Isakov Bakhtiyor

Muydinovich,

²Isakov Kuvonchbek
Bakhtiyorovich

EMAIL : bakhtiyor_adti@mail.ru

Received 20th February 2021,

Accepted 27th February 2021,

Online 28th February 2021

^{1,2} Andijan State Medical Institute,
Uzbekistan

ABSTRACT: It is known that injuries and diseases of the cervical spine are distinguished by the complexity and originality of the clinical course. On the example of the treatment of 34 patients, we carried out a specific study, the purpose of which was to determine the optimal surgical method for stabilizing the cervical spine in trauma and degenerative lesions. When determining the method of choice, we were guided not only by the reliability and availability of the method, but also by the timing of early activation of patients in the postoperative period. The advantage of using static nickelide titanium implants in terms of functional outcome and length of hospital stay was revealed.

Key words: trauma, titanium implants, hospital.

Relevance of the topic

Complicated pathology of the cervical spine caused by trauma or degenerative-dystrophic lesions is one of the most severe types of pathology. Lesions of the cervical spinal cord arising in this type of pathology lead to the appearance of a complex complex of structural and functional changes manifested in the form of a gross neurological deficit, diverse neurotrophic, metabolic, dyscirculatory disorders and infectious complications that significantly aggravate the course of the pathological process [3, p. ... 52]. The known methods of conservative therapy for this pathology rarely lead to positive results, are accompanied by a large number of complications, high mortality and disability of patients [1. from. 43]. The most significant factor that positively affects the immediate and long-term treatment outcomes of this group of patients is timely, adequate surgical intervention [1. from. 45].

The need to perform surgical approaches with anterior compression of the cervical spinal cord in the overwhelming majority of cases is not in doubt [2. from. 16].

Difficulties in reliable stabilization of the cervical spine, due to the anatomical and physiological features of the structure and high functional load of this section, led to the

creation of a large number of materials and structures currently used for these purposes, which indicates that the problem has not been resolved [2. from. 25].

Purpose of the study

Improving the efficiency of anterior stabilization of the cervical spine by optimizing anterior interbody fusion based on the use of titanium nickelite implants of various designs.

Material and research methods

In the present study, 34 patients were studied and analyzed, who were operated on for spinal cord injury - 21 (59.8%) and degenerative-dystrophic lesions - 13 (40.2%). The patients were examined and treated at the clinic of the Andijan State Medical Institute, the Andijan branch of the Republican Scientific Center for Emergency Medical Aid in the period from 2016 to 2019.

The patients were conditionally divided into three groups.

The first group of patients who underwent ventral stabilization of the cervical spine using a carbon implant included 24 patients. The causes of damage to the cervical spine were trauma in 14 patients, degenerative-dystrophic changes in 10 patients.

The second group consisted of 6 patients, who underwent ventral stabilization of the cervical spine with static implants made of porous titanium nickelite. The causes of damage to the cervical spine were trauma in 4 patients, degenerative-dystrophic changes in 2.

The third group included 4 patients with discogenic cervical myeloradiculopathy, for whom layered porous titanium nickelite implants were used for anterior stabilization.

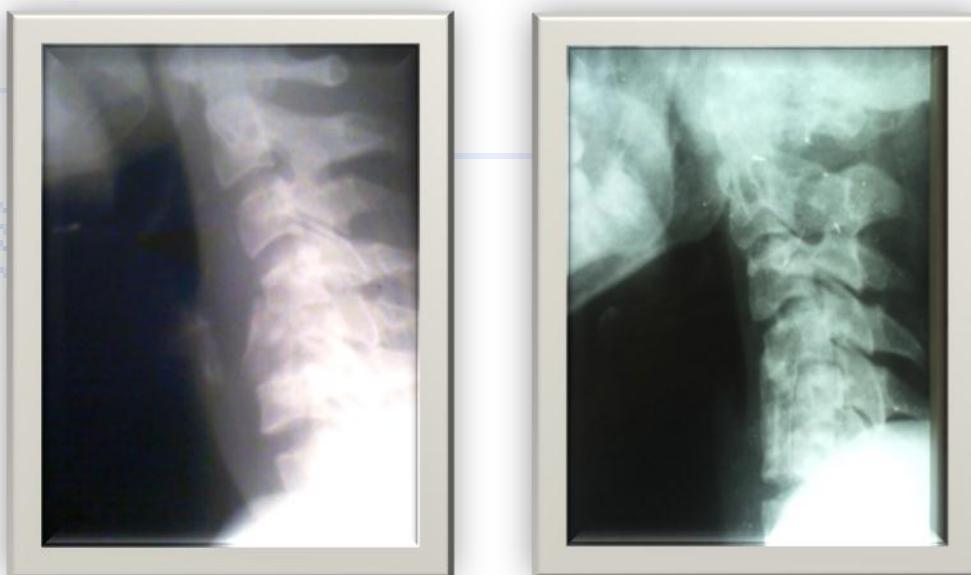


Figure 1. Patient M. - the operation was performed "open reduction of dislocation of the C5 vertebra. C5 vertebral body resection and anterior stabilization with a carbon implant

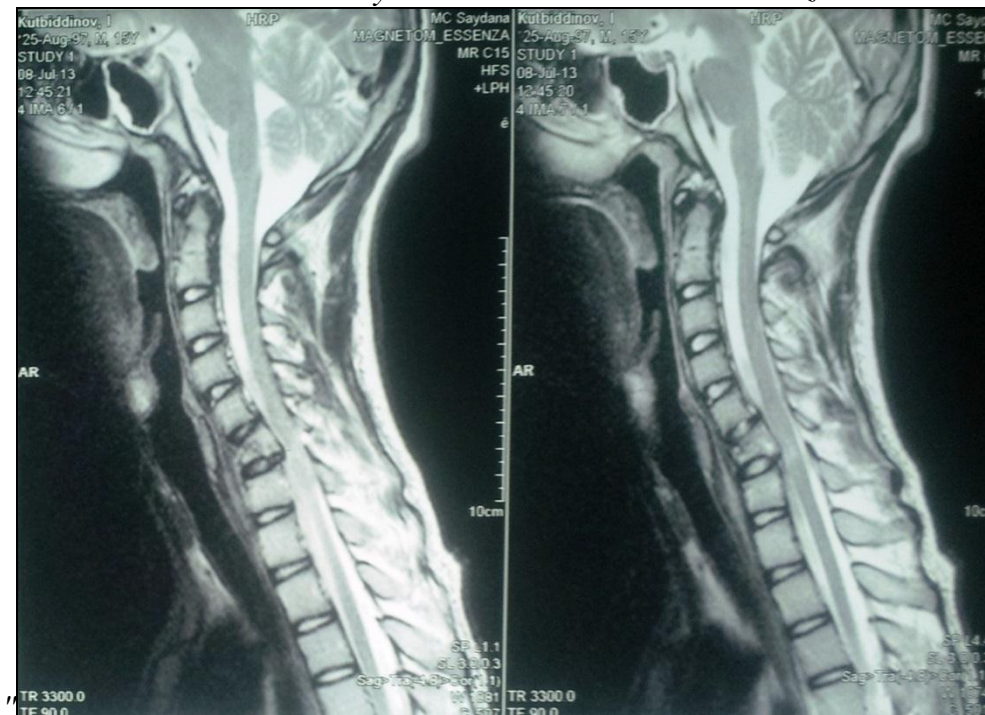
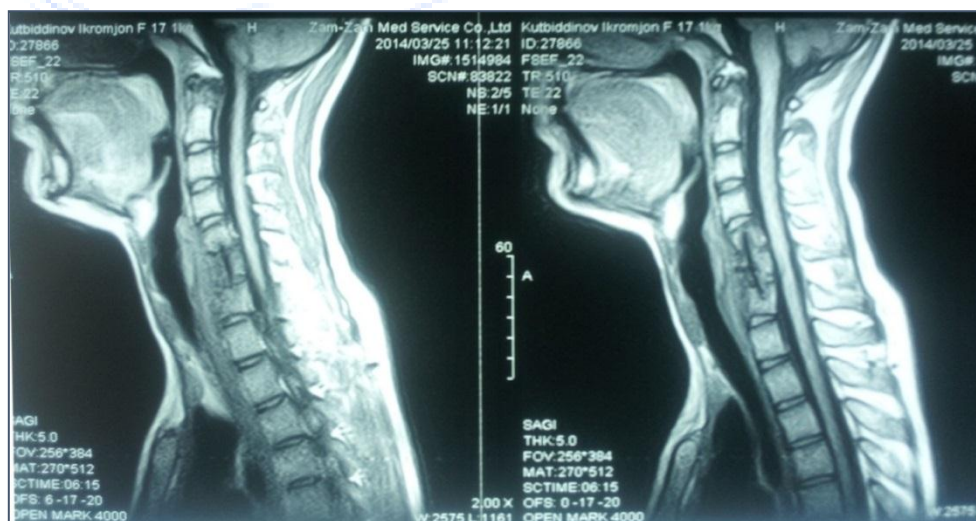

Figure 2. Patient K. - condition before and after the operation "Open reduction of dislocation C6. Resection of the C6 vertebral body. Anterior fusion of C5-C7 vertebrae with carbon implant "



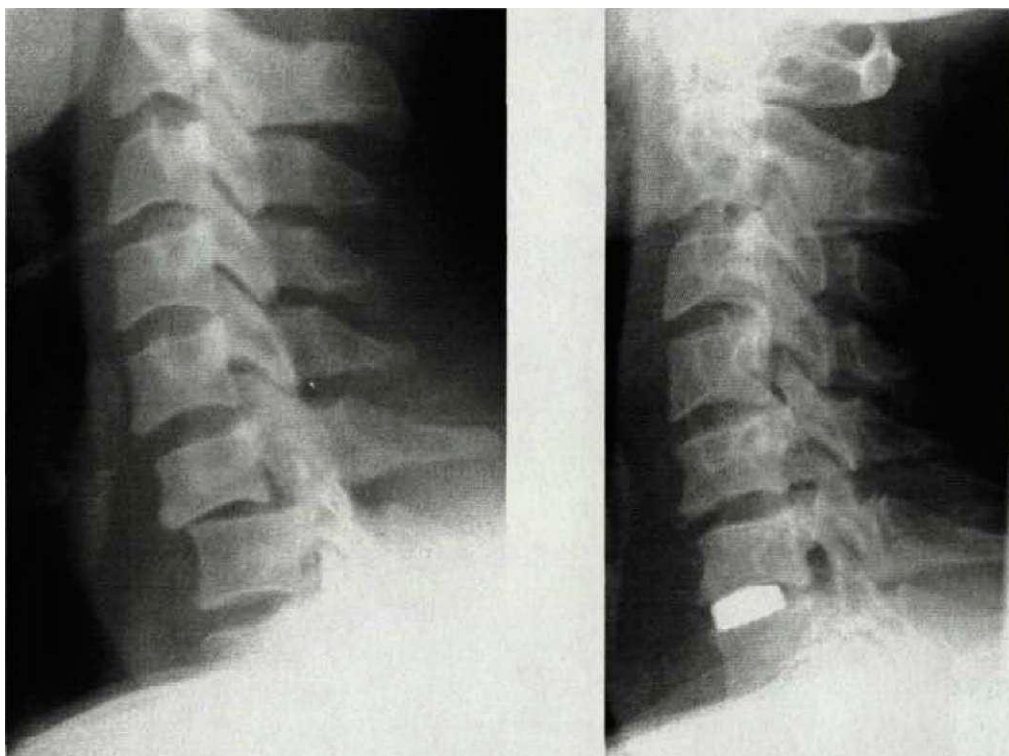


Figure 3. Patient P. Diagnosis: complicated dislocation of the C6 vertebral body.

Operation: "Open reduction of the dislocation of the C6 vertebra. Anterior discectomy. Fixation with a dynamic titanium implant "

Research results and their discussion. When evaluating the study data, during which satisfactory and good results were obtained in patients of all three groups, we relied on the timing of discharge from the hospital.

Length of hospital stay for patients with degenerative-dystrophic lesions of the cervical spine, depending on the method of anterior stabilization $n = 70$ ($M \pm m$)

Stabilization method	Number of patients	Average length of hospital stay (days)
Spinal fusion with carbon implants	24	32,3
Spinal fusion with static titanium implants	6	21,4
Spinal fusion with dynamic titanium implants	4	14,3

Conclusion

Thus, anterior spondylodesis with static titanium nickelide implants in patients with complicated cervical spine trauma provides sufficiently reliable stabilization of the spinal segment, does not require additional external immobilization, facilitates rehabilitation measures in the early postoperative period, and reduces the length of stay of patients in hospital.

References:

1. Lutsik A.A. Injuries and diseases of the spine and spinal cord // Surgery of the spine and spinal cord. - Novokuznetsk, 2005. -S.3-10.

2. Livshits A.B., Kubanova E.H. Scientific and organizational issues of treatment of patients with spinal cord injury // Injury of the cervical spine and spinal cord. -C., 2007. -C. 12-15.
3. Protsenko AI, Uchnik P. Spondylodesis with polymer fixation in the rehabilitation of patients with complicated injuries of the cervical vertebrae // Fundamental and applied issues of rehabilitation of patients with spinal cord injury: Sat. Art. / Ministry of Health of the USSR and others / Ed. V.V. Morozova and others - Simferopol, 2009. -S. 172-175.
4. Cake H.A. Degenerative instability of the cervical spine: diagnosis and treatment principles. Osteochondrosis of the spine. -M., 2002., 2010 - S. 71-77.

