



Morphological and Orthometric Parameters of Lymphoid Structures of the Spleen of White Rats

1. Turdiyev Mashrab Rustamovich

Received 27th Jul 2021,
Accepted 29th Aug 2021,
Online 04th Oct 2021

¹ Bukhara State Medical Institute,
Republic of Uzbekistan, Bukhara

Abstract: The article studies the structural parameters of the spleen of white rats in postnatal ontogenesis in the dynamics of age. It was found that in postnatal ontogenesis, the morphological and morphometric parameters of the white pulp of the spleen of white rats undergo significant changes, which is reflected in different age aspects. In newborn white rat pups, the spleen is functionally immature. At three and six months of age, the spleen has the maximum potential for immunogenesis. At the age of twelve months, the processes of age-related involution of the organ begin, which are expressed by changes in the structure of the white pulp of the spleen.

Keywords: rats, spleen, white pulp, age-related changes, morphometric parameters.

Relevance. The immune system is one of the adaptation mechanisms of the organism, which plays an important role in maintaining its antigenic homeostasis [7, 8, 9, 14, 15].

The interest of morphologists in the study of the structure of the spleen, associated with the intensive development of immunology, is steadily growing [6, 11, 13, 17]. The spleen is a large peripheral organ of immunogenesis, which expresses the state of immunity in humans and animals, as well as of its structural formations [12, 16]. The spleen is a parenchymal organ, represented by the pulp and connective tissue stroma, which is formed by the capsule, trabeculae, reticular framework [1,4].

The spleen parenchyma consists of two functional zones, red and white pulp, with different structures and functions [2, 3, 10]. Currently, an urgent problem is the study of the lymphoid structures of the spleen, which is responsible for the effectiveness of the cellular and humoral immune response of both innate and acquired immunity [5].

Objective: to study the morphological and morphometric parameters of the lymphoid structures of the spleen of white outbred rats in postnatal ontogeny in the dynamics of age.

Materials and research methods. The study was carried out on 54 white outbred male rats, weighing from 5 to 280 grams, which were kept under standard vivarium conditions. The animals were divided into five age groups: group 1 - newborns (n = 10), group 2 - 90 day old rats (n = 12), group 3 - 180 day old rats (n = 10), group 4 - 270 day old rats (n = 12), 5th group - 360 day old rats (n = 10). All experimental studies on animals were carried out in accordance with the "Rules for work using

experimental animals."

The animals were weighed, taken out of the experiment in a newborn, 90, 180, 270, 360 days of age by instant decapitation under ether anesthesia. The spleen was removed from the abdominal cavity. The absolute mass of the spleen was determined using a torsion balance, its linear dimensions: length, width and thickness using a caliper. The mass index of the spleen was calculated using the formula $MI = M_{\text{spleen}} * 100 / M_{\text{animals}}$, where M is the mass.

To carry out the morphological and morphometric study of the study, spleen fragments were fixed in 10% formalin solution, passed through a battery of alcohols, and embedded in paraffin blocks according to generally accepted methods. Paraffin sections 5–8 μm thick were stained with hematoxylin - eosin. Sections were examined morphometrically, using an eyepiece micrometer DN-107T / Model NLCD-307B (Novel, China), the diameter of the periarterial lymphatic muffs, lymph nodules and their germinal centers, the width of the mantle, marginal and periarterial zones, the relative area of the white pulp and connective tissue elements of the spleen were measured. ... Measurements were performed in five fields of view of each histological section. The fields of view were chosen at random.

In order to study the cytoarchitectonics of the lymphoid structures of the spleen, cells were counted using a NOVEL Model NLCD-307 microscope, at a magnification of $10 * 90$, under oil immersion. Cells were counted using a morphometric grid mounted in the eyepiece ($10 *$) of the microscope.

The total number of lymphocytes, the number of large, medium and small lymphocytes per unit section area in PALM, in lymphoid nodules without a proliferation center were counted.

Mathematical processing was carried out directly from the general data matrix "Excel 7.0" on a Pentium-IV personal computer using the capabilities of the "STTGRAPH 5.1" program, the indices of the standard deviation and the error of representativeness were determined.

Research results. Outside, the spleen of newborn white rat pups is covered with a capsule, which consists of a thin connective tissue. Trabeculae containing arteries and veins depart from the capsule deep into the organ. In the parenchyma of the spleen, red and white pulps are isolated. On a histological section, the red pulp of the spleen consists of venous sinuses and splenic tracts located between them. White pulp in newborn rat pups is visually indistinct periarterial lymphatic muffs (PALM) and lymphoid nodules (LN). In single primary lymphoid nodules, the mantle (MnZ) and marginal zones (MGZ) can be identified. At this age, germinal centers (HC) are not yet detected in the LU.

Studies have shown that the mass of newborn animals is in the range from 4.4 g to 5.8 g on average 5.18 ± 0.15 g. The absolute mass of the organ is 0.02-0.04 g, on average 0.032 ± 0.002 g. the index ranges from 0.545% to 0.674%, on average $0.617 \pm 0.014\%$.

The length of the spleen of newborn rat pups ranges from 5.4 mm to 8.4 mm, on average 7.2 ± 0.32 mm. The width of the spleen is in the range of 1.4-2.9 mm, on average - 2.12 ± 0.16 mm. The spleen thickness varied from 0.8 mm to 1.8 mm, on average - 1.2 ± 0.11 mm.

The relative area of the white pulp ranges from 14.2 -20.1%, on average - $17.16 \pm 0.64\%$. The relative area of connective tissue elements varied from 5.2% to 6.5%, on average - $5.94 \pm 0.16\%$ (to the total area of the spleen section).

The PALM diameter ranges from 90.2 μm to 109.2 μm , on average 100.2 ± 2.05 μm . The LA diameter is 218.4-252.2 microns, on average 242.76 ± 3.65 microns. In a third of the total number of nodules, the mantle and marginal zones can be distinguished.

The width of the mantle zone is 28.4 μm to 38.3 μm , with an average of 35.28 ± 1.07 μm . The width

of the marginal zone ranges from 56.3 microns to

69.7 microns, on average 64.32 ± 1.45 microns. The width of the periarterial zone is 38.6 μm to 48.4 μm , on average 44.16 ± 1.06 μm .

The white pulp is formed predominantly from lymphocytes at various stages of maturation. There are small, medium and large lymphocytes.

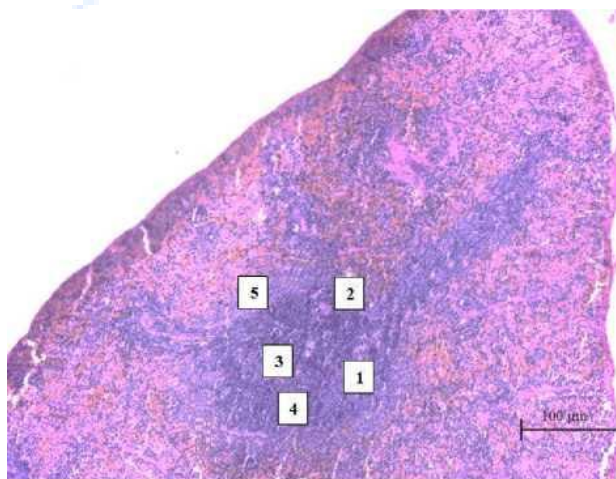
In three-month-old white rats, the spleen is already formed. When examining the spleen of 3 month old intact rats, the following data were obtained:

The mass of animals of 3 months of age is in the range from 90 g to 130 g, on average 114.16 ± 3.6 g. The absolute mass of the organ is 0.3 - 0.7 g, on average - 0.52 ± 0.037 g. The mass index ranges from 0.333% to 0.551%, on average $0.455 \pm 0.024\%$.

The length of the spleen ranges from 22.4 to 29.2 mm, with an average of 26.78 ± 0.63 mm. The width of the spleen is in the range of 4.6-7.4 mm, on average 5.94 ± 0.26 mm. The spleen thickness varied from 1.8 mm to 3.9 mm, on average 2.92 ± 0.19 mm.

In histopreparations of the spleen of 3-month-old intact rats, a more distinct division of the organ parenchyma into red and white pulp was observed. The relative area of the white pulp ranges from 19.8% to 26.2%, on average $22.2 \pm 0.59\%$. The relative area of connective tissue elements varied from 5.0% to 6.1%, on average - $5.52 \pm 0.1\%$ (to the total area of the spleen section).

In the white pulp, periarterial lymph nodes (PALM) and lymphoid nodules (LN) can be clearly distinguished. The PALM diameter ranges from 122.6 microns to 139.6 microns, on average 132.14 ± 1.56 microns. The diameter of the lymph nodules increases 92% in comparison with newborn rat pups and ranges from 341.8 μm to 486.05 μm , on average 466.05 ± 13.27 μm . LU can be visually divided into primary and secondary, which percentage is 32% and 68%, respectively. In the secondary LUs, the formed germinal centers are determined. The diameter of germinal centers fluctuates from 94.6 microns to 167.8 microns, on average 147.8 ± 6.73 microns. LUs are large, often confluent. The LU of the white pulp of the spleen is generally rounded, oval and elongated.



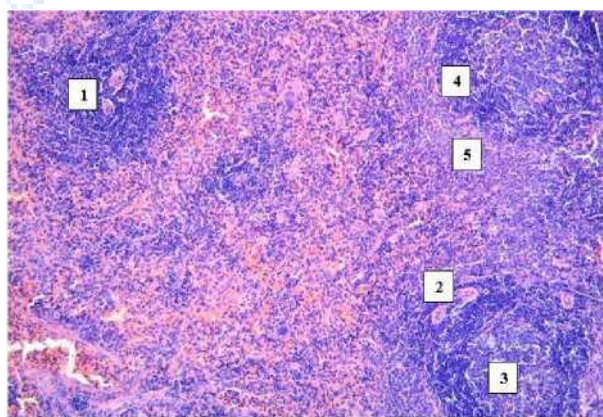
Rice. 1. Spleen of a 3-month-old rat of the control group. Staining with hematoxylin - eosin. OK. 10 x vol. 20.1- lymphatic nodule, 2periarterial zone, 3- germinal center, 4- mantle zone, 5- arginal zone.

In most cases, the LN zones are well distinguishable. The width of the mantle zone ranges from 39.7 microns to 49.45 microns, on average 45.32 ± 0.89 microns. The width of the marginal zone ranges from 70.3 μm to 84.7 μm , on average 77.14 ± 1.32 μm . The width of the periarterial zone ranges from 81.9 μm to 89.4 μm , on average 85.04 ± 0.69 μm (Fig. 1). It was found that the total number of

lymphocytes in LN without proliferation centers is 42-53, on average 47.3 ± 1.01 cells. Lymphoid nodules without proliferation centers contain (per unit area) small lymphocytes - 30-38, on average - 34.0 ± 0.74 cells, average lymphocytes 10-12, on average - 11.0 ± 0.18 cells, large lymphocytes - 2-3, on average - 2.3 ± 0.1 cells. The total number of lymphocytes in the periarterial lymphoid muffs of the white pulp of the spleen is 41-53, on average - 47.2 ± 1.1 cells. Periarterial lymphoid clutches contain (per area unit) small lymphocytes -2937, on average - 33.0 ± 0.74 cells, average lymphocytes - 9-11, on average - 10.25 ± 0.18 cells and large lymphocytes -3 -4, on average - 3.5 ± 0.1 cells. The weight of 6-month-old animals is in the range from 190 g to 240 g, on average 220.2 ± 5.4 g. The absolute mass of the organ is 0.6-0.9 g, on average 0.79 ± 0.032 g. The mass index ranges from 0.315% to 0.405%, on average $0.358 \pm 0.01\%$. The length of the spleen ranges from 26.4mm to 35.7mm, with an average of 31.76 ± 1.0 mm. The width of the spleen is in the range of 4.9-7.7 mm, on average - 6.34 ± 0.03 mm. The spleen thickness varied from 2.4 mm to 4.2 mm, on average - 3.12 ± 0.19 mm. In 6 month old rats of the control group, the relative area of the white pulp of the spleen ranges from 18.2 to 24.6%, on average $20.54 \pm 0.69\%$. The relative area of connective tissue elements varied from 5.6% to 6.7%, on average - $6.21 \pm 0.12\%$ (to the total area of the spleen section). The PALM diameter ranges from 128.2 microns to 141.6 microns, on average 136.22 ± 1.55 microns. The diameter of the lymph nodules ranges from 380.8 microns to 477.05 microns, on average 420.96 ± 10.44 microns. The percentage of primary and secondary LUs is 34% and 66%, respectively. The diameter of the germinal centers ranges from 122.4 μ m to 147.7 μ m, on average 135.08 ± 2.73 μ m. The LU of the white pulp has a rounded, oval and elongated shape.

In microslides, all the LN zones can be visually distinguished. The width of the mantle zone is from 40.5 microns to 50.4 microns, on average 46.56 ± 1.06 microns. The width of the marginal zone ranges from 74.5 microns to 86.2 microns, on average 80.72 ± 1.26 microns. The width of the periarterial zone ranges from 84.9 μ m to 94.7 μ m, on average 89.42 ± 1.06 μ m (Fig. 2).

It was found that the total number of lymphocytes in LN without centers of reproduction is 52-61, on average, 57.2 ± 0.97 cells. Lymphoid nodules without reproduction centers contain (per unit area) small lymphocytes - 37-43, on average - 41.0 ± 0.65 cells, average lymphocytes 12-14, on average - 13.0 ± 0.22 cells, large lymphocytes - 3-4, on average - 3.2 ± 0.11 cells.



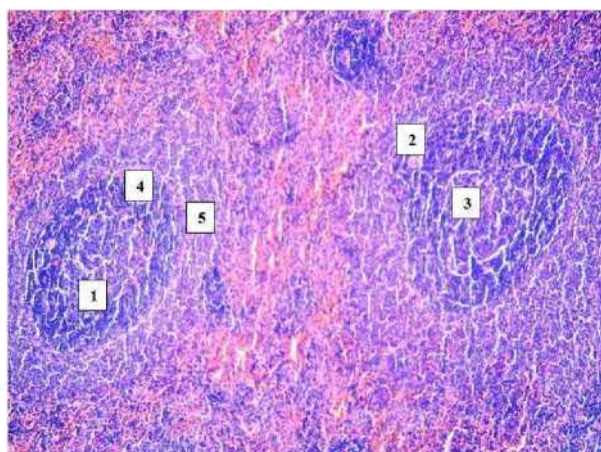
Rice. 2. The spleen of a 6-month-old rat of the control group. Staining with hematoxylin - eosin. OK. 10 x vol. 20.1- lymph node, 2periarterial zone, 3- germinal center, 4- mantle zone, 5-marginal zone.

The total number of lymphocytes in the periarterial lymphoid muffs of the white pulp of the spleen is 53-61, on average, 58.4 ± 0.86 cells. Periarterial lymphoid clutches contain (per unit area) small lymphocytes -3843, on average - 41.0 ± 0.54 cells, medium lymphocytes - 11-13, on average - 12.0 ± 0.22 cells and large lymphocytes -5 -6, on average 5.4 ± 0.11 cells.

The weight of 9-month-old laboratory animals is in the range from 220 g to 280 g, on average 256.33 ± 5.52 g. The absolute mass of the organ is 0.7-1.0 g, on average 0.84 ± 0.028 g. The mass index ranges from 0.302% to 0.370%, on average $0.327 \pm 0.006\%$. The length of the spleen ranges from 30.3 mm to 38.4 mm, on average 34.21 ± 0.74 mm. The width of the spleen ranges from 5.1 to 7.9 mm, on average 6.52 ± 0.26 mm. The spleen thickness varied from 2.5 mm to 4.4 mm, on average 3.21 ± 0.17 mm.

In 9 month old rats of the control group, the relative area of the white pulp of the spleen ranges from 18.1% to 22.4%, on average $20.14 \pm 0.39\%$. The relative area of connective tissue elements varied from 5.7% to 6.8%, on average $6.33 \pm 0.1\%$ (to the total area of the spleen section).

The PALM diameter ranges from 132.2 microns to 142.3 microns, on average 137.72 ± 0.93 microns. The diameter of the lymph nodules ranges from 378.7 microns to 447.3 microns, on average 414.84 ± 6.31 microns. The percentage of primary and secondary LUs is 35% and 65%, respectively. The diameter of germinal centers ranges from 115.4 microns to 142.8 microns, on average 127.62 ± 2.52 microns. The LU of the white pulp has a rounded, oval and elongated shape. In most cases, the LN zones are well distinguishable. The width of the mantle zone ranges from microns to 49.9 microns, on average 44.76 ± 1.06 microns. The width of the marginal zone ranges from 70.1 μm to 82.4 μm , on average 76.34 ± 1.13 μm . The width of the periarterial zone ranges from 78.7 μm to 92.8 μm , on average 84.97 ± 1.29 μm (Fig. 3).



Rice. 3. Spleen of a 9-month-old rat of the control group. Stained with hematoxylin - eosin. Approx. 10 x vol. 20.1- lymphatic nodule, 2- periarterial zone, 3- germinal center, 4- mantle zone, 5- marginal zone.

It was found that the total number of lymphocytes in LN without proliferation centers is 48-56, on average, 52.2 ± 0.74 cells. Lymphoid nodules without reproduction centers contain (per unit area) small lymphocytes - 36-41, on average 39.0 ± 0.46 cells, average lymphocytes 10-12, on average 11.0 ± 0.18 cells, large lymphocytes - 2-3, on average 2.2 ± 0.1 cells.

The total number of lymphocytes in the periarterial lymphoid muffs of the white pulp of the spleen is 56-65, on average, 60.3 ± 0.83 cells. Periarterial lymphoid clutches contain (per unit area) small lymphocytes - 40-46, on average 43.0 ± 0.55 cells, medium lymphocytes - 12-14, on average 13.0 ± 0.18 cells and large lymphocytes - 4 -5, on average 4.2 ± 0.1 cells.

The mass of white rats of 12 months of age in the control group is in the range from 260 to 320 g, on average 282.44 ± 6.48 g. The absolute mass of the organ is 0.8 - 1.1 g, on average 0.88 ± 0.03 g. The mass index is in the range from 0.288% to 0.354%, on average $0.315 \pm 0.007\%$.

The length of the spleen ranges from 34.4 mm to 2.7 mm, with an average of 36.57 ± 0.89 mm. The width of the spleen is in the range of 5.3-8.2 mm, on average - 6.56 ± 0.31 mm. The spleen thickness varied from 2.7 mm to 4.6 mm, on average 3.23 ± 0.20 mm.

In 12 month old white rats of the control group, the relative area of the white pulp of the spleen ranges from 16.2% to 20.8%, on average - $18.54 \pm 0.49\%$. The relative area of connective tissue elements varied from 5.8% to 6.8%, on average - $6.48 \pm 0.11\%$ (to the total area of the spleen section). The PALM diameter ranges from 131.4 μm to 142.8 μm , with an average of 136.56 ± 1.23 μm . The diameter of the lymph nodules ranges from 370.7 microns to 437.3 microns on average 407.98 ± 7.19 microns. The percentage of primary and secondary LUs is 49% and 51%, respectively. HZs are poorly expressed. The diameter of the germinal centers ranges from 110.2 microns to 132.7 microns, on average 120.02 ± 2.43 microns. The LU of the white pulp has an oval and elongated shape.

Conclusions. In postnatal ontogenesis, structural and functional transformations are observed in the spleen of white rats, which is reflected in the formation of a white pulp. In newborn white rat pups, the spleen is functionally immature, with hardly distinguishable zones and single formed lymphoid nodules. At three and six months of age, the spleen has the maximum potential for immunogenesis. At the age of twelve months, the processes of age-related involution of the organ begin, which are manifested by an increase in the relative area of the connective tissue elements, a decrease in the relative area of the PD, the diameter of the PALM, LN, HC, as well as the width of the mantinea, the marginal, periarterial zone of the lymph nodes of the spleen.

References

1. Turdiyev M.R., Teshayev Sh.J. Morphometric assessment of functional immunomorphology of white rat spleen in the age aspect // American Journal of Medicine and Medical Sciences. – 2019. –9(12) – P.523-526.
2. Turdiyev M.R., Teshayev Sh.J., Sohibova Z.R., Uktamova R.U. Morphological parameters of structures of the spleen of white rats in normal and on the background of chronic radiative disease // Новый день в медицине. – 2020. – 2/1 (30/1) – P.175-177.
3. Турдиев М.Р., Тешаев Ш.Ж. Сравнительная характеристика морфологических и морфометрических параметров селезенки белых крыс в норме, хронической лучевой болезни и при коррекции биостимулятором // Биология ва тиббиёт муаммолари – 2020. – №4 (120) – С.160-165 (14.00.00. №19)
4. Турдиев М.Р. Морфофункциональные особенности селезенки белых крыс в норме и при хронической лучевой болезни // Новый день в медицине. – 2020. –3 (31) – С.734-737
5. Turdiev M.R., Teshaev Sh.J. Comparative characteristics of the spleen of white rats in normal and chronic radiation sickness // EPRA international journal of Research and Devolepment (Online). 2020. Volume: 5 Issue: 8. P.212-216
6. Turdiev M.R., Teshaev Sh.J. Features of the morphological structure of the spleen of white rats in normal and chronic radiation sickness in postnatal ontogenesis //International scientific and practical conference, Paris, 29.09.2020-30.09.2020, P.91-93.
7. Balogh P., Horvath G., Szakal A. K. // J. Histochem. Cytochem. - 2004. - Vol. 52, № 10. - P. 1287-1298. Balogh P., Horvath G., Szakal A. K. // J. Histochem. Cytochem. - 2004. - Vol. 52, № 10. - P. 1287-1298.
8. Mebius R. E. Structure and function of the spleen/R. E. Mebius, G. Kraal//Nat. Rev. Immunol. 2005. -№ 5. - P. 606-616.Mebius R. E. Structure and function of the spleen/R. E. Mebius, G. Kraal//Nat. Rev. Immunol. 2005. -№ 5. - P. 606-616.

9. Teshayev Sh.J., Khasanova D.A / Topograficanatomical features of lymphoid structures of the small intestine of rats in norm and against the background of chronic radiation diseases // European science review Vienna, Austria №9-10 2018, Volume 2. Medical science - P. 197-198
10. Turdiyev M.R., Teshayev Sh.J., Sohibova Z.R., Uktamova R.U. / Morphological parameters of structures of the spleen of white rats in norm and on the background of chronic radiation disease // Новый день в медицины. 2020.2/1 (30/1). - С. 175-177.
11. Молдавская А.А. Морфологические критерии строения селезенки в постнатальном онтогенезе / А.А. Молдавская, А.В. Долин // Успехи современного естествознания. - 2009. - № 2 - С. 15-18.
12. Рябикина А. И. [и др.] Онтогенетические аспекты стромально-паренхиматозных взаимоотношений в селезенке / // Морфология. - 2008. - Т. 132, № 2. - С. 58.
13. Сапин М. Р. Иммунная система, стресс и иммунодефицит/М. Р. Сапин, Д. Б. Никитюк. - М.: АПП «Джангар». - 2000. - С. 176-184.

